

# 2022

## ORTHOSPORTS

Orthopaedic & Sports Medicine Service



## LATEST ORTHOPAEDIC UPDATES



[www.orthosports.com.au](http://www.orthosports.com.au)



---

				<b>Doctors Consulting here</b>
<b>Concord</b>	47-49 Burwood Road CONCORD NSW 2137	Tel Fax	<b>02 9744 2666</b> <b>02 9744 3706</b>	Dr Todd Gothelf Dr Samya Lakis Dr David Lieu Dr Paul Mason Dr John Negrine Dr Doron Sher Dr Christopher Spelman Dr Kwan Yeoh
<hr/>				
				<b>Doctors Consulting here</b>
<b>Hurstville</b>	Level 7 Waratah Private 29-31 Dora Street HURSTVILLE NSW 2220	Tel Fax	<b>02 9580 6066</b> <b>02 9580 0890</b>	Dr Paul Annett Dr Jerome Goldberg Dr Michael Goldberg Dr Todd Gothelf Dr Samya Lakis Dr Andreas Loeffler Dr John Negrine Dr Ivan Popoff Dr Kwan Yeoh
<hr/>				
				<b>Doctors Consulting here</b>
<b>Penrith</b>	Suite 5B 119-121 Lethbridge St PENRITH NSW 2750	Tel Fax	<b>02 4721 7799</b> <b>02 4721 7997</b>	Dr Todd Gothelf Dr Christopher Spelman Dr Kwan Yeoh
<hr/>				
				<b>Doctors Consulting here</b>
<b>Randwick</b>	160 Belmore Road RANDWICK NSW 2031	Tel Fax	<b>02 9399 5333</b> <b>02 9398 8673</b>	Dr John Best Dr Jerome Goldberg Dr Leigh Golding Dr Todd Gothelf Dr Samya Lakis Dr Andreas Loeffler Dr John Negrine Dr Ivan Popoff Dr Doron Sher Dr Christopher Spelman
<hr/>				
				<b>Doctors Consulting here</b>
<b>Bella Vista</b>	Suite 116, Level 1 Bldg B20, Lexington Drive BELLA VISTA NSW 2153	Tel Fax	<b>02 9744 2666</b> <b>02 9744 3706</b>	Dr Kwan Yeoh
<hr/>				
				<b>Doctors Consulting here</b>
<b>Canberra</b>	Lvl 2, 90 Corinna Street PHILLIP ACT 2606	Tel	<b>02 9580 6066</b>	Dr Samya Lakis Dr Christopher Spelman

---

# ORTHOSPORTS

Time	Event	Who
<b>07:30 – 08:00</b>	Arrival / Refreshments	
<b>08:00</b>	Welcome Message	Dr Doron Sher
	WALANT - How to stay wide awake and comfortable during your hand operation.	Dr Kwan Yeoh
	Complex region pain syndrome of the foot & ankle	Dr Todd Gothelf
	Sesamoids and accessory bones of the foot & ankle	Dr John Negrine
<b>08.55</b>	Panel Discussion	
	Imaging in Musculoskeletal Assessment	Dr Paul Annett
	Common Paediatric Fractures	Dr Samya Lakis
	Paediatric ACL Injuries, an update on management	Dr Chris Spelman
	Dual Mobility Hip Replacements	Dr Andreas Loeffler
<b>10.20</b>	Panel Discussion	
<b>10.45-11.15</b>	<b>Morning Tea</b>	
	Physio question, education, Sponsor	
	Knee Joint Examination	Dr Paul Mason & Dr Doron Sher
	Management of Difficult Rotator Cuff Tears	Dr Ivan Popoff
	Assessing Rotator Cuff Deficiency	Dr John Best
	Shoulder Instability	Dr Doron Sher
<b>12.30</b>	Panel Discussion & Close	

## **Dr Kwan Yeoh**

*M.B., B.S. (Hons) (Syd), F.R.A.C.S. (Ortho)*

*Hand, Wrist, Upper Limb & General Orthopaedics*



# **How to stay wide awake and comfortable during your hand operation**

## **HISTORY OF ANAESTHESIA**

- No anaesthesia
- General anaesthesia
- Local anaesthesia
- WALANT
  - Wide Awake Local Anaesthesia No Tourniquet

## **ADVANTAGES**

- Safer than general anaesthesia
  - No after-effects of general anaesthesia
- Surgical repairs can be tested during surgery
- Cost savings

## **DISADVANTAGES**

- Cost savings limited by policies designed to save costs
  - Out-of-hospital procedures are limited

## **SUITABLE PROCEDURES**

- Tendon stenosis
  - Trigger digit release
  - De Quervains release
- Nerve compressions
  - Open carpal tunnel release
  - Open cubital tunnel release
- Tendon repairs
- Tendon transfer
- Finger fracture fixation
- Dupuytren's contracture release

**Dr Kwan Yeoh**

*M.B., B.S. (Hons) (Syd), F.R.A.C.S. (Ortho)*

*Hand, Wrist, Upper Limb & General Orthopaedics*



**RELATIVE CONTRAINDICATIONS**

- Complex procedures
- Deep tissue procedures
- Documented allergy to lignocaine
- Compromised peripheral vascular system
- Patient factors
  - Prefers general anaesthesia
  - Anxious
  - Likely to move
- Paediatric
- Infection at site of surgery

## **Complex Region Pain Syndrome of the Foot and Ankle**

Complex Region Pain Syndrome (CRPS) was first described by Silas Weir Mitchell, a Physician who worked with nerve injuries in soldiers. In 1864 he described a “burning pain” experienced by injured soldiers in the US Civil War. He came up with new treatments for nerve damaged men, prescribing rest, along with massage and overfeeding. His treatment became known as a “Rest Cure”.

CRPS has been known by many different names, such as Reflex Sympathetic Dystrophy (RSD), Post-traumatic dystrophy, causalgia, Sudeck Atrophy. In 1993 the International Association for the Study of Pain (IASP) came up with the name Complex Regional Pain Syndrome and described two types, CRPS I and CRPS II. Both are described by the same set of symptoms and only difference is that CRPS II (Causalgia) involves an injury to a peripheral nerve which led to the symptoms. Both CRPS I and CRPS II have the following characteristics:

- CRPS1
  - Development of symptoms after an initial event, that may or may not be traumatic
- CRPSII, a definable peripheral nerve injury.
  - Development of symptoms after a nerve injury or an initial painful event.
- Both have the following characteristics:
  - Sensory
    - Hyperalgesia/hyeraesthesiae- An abnormally increased sensitivity to pain.
    - Allodynia- Pain is caused by a stimulus that does not normally elicit pain (light touch).
  - Vasomotor- symptoms due to constriction or dilation of blood vessels thought due to abnormal sympathetic function or norepinephrine.
    - Temperature asymmetry. Hot or cold differences. Some reports indicated infrared thermometer must be a 1 degree C difference.
    - Skin colour changes
  - Sudomotor- Refers to the autonomic nervous system control of sweat gland activity.
    - Oedema- swelling asymmetrical and can recur randomly throughout the day.
    - Sweating- hyperhidrosis- excess sweating not related to heat or exercise.
  - Motor/Trophic
    - Decreased range of motion
    - Motor dysfunction
      - Tremor- an involuntary movement/shaking
      - Dystonia- a neurological hyperkinetic movement disorder with sustained or repetitive muscle contractions result in twisting and repetitive movements or abnormal fixed postures.
    - Trophic Changes
      - Hair- loss of hair
      - Nails- change in appearance of nails, dis-coloration, brittleness, lines in the Nail bed.
      - Skin- glossy appearance with loss of hair.

## Dr Todd Gothelf

MD (USA), FRACS, FAAOS, Dip ABOS

Foot, Ankle, Shoulder Surgery



- There is no other diagnosis that better explains the signs and symptoms. This means that the following tests are reasonably ordered when a patient presents with symptoms. To diagnose CRPS the following tests may all be normal and therefore do not help to explain the signs and symptoms:
  - MRI is normal
  - X-rays- general osteopaenia but no fracture, no arthritis. X-rays may also be normal.
  - Three Phase Bone scan- Shows increased blood flow, pooling, and delayed periarticular uptake in the affected limb. The bone scan may also be normal
  - EMG/NCS- rule out nerve injury, should be normal
  - Blood tests, ESR/CRP- should be normal indicative of no infection.

## TREATMENT

Once a Diagnosis is made, it is important to initiate treatment, as early treatment is the single best predictor of success in the management of CRPS. Treatment involves a multidisciplinary approach, with Pain Management, Physiotherapy, and Psychological Support.

Physiotherapy involves desensitisation, and gentle movement to regain flexibility and control oedema. Physiotherapy should not be aggressive so as not to exacerbate symptoms.

Referral to a Pain Management Specialist is reasonable to initiate treatments which include medical management and possible nerve blocks such as lumbar sympathetic blocks.

## PREVENTION

A meta-analysis has shown that Vitamin C given after surgery or injury is effective in preventing the development of CRPS. The daily dose of Vitamin C used was 500 mg or 1g per day for 42 to 50 days, given just after surgery or injury. This was associated with a lower rate of CRPS-I than a placebo, while no differences were found with respect to complications, functional outcomes, and pain scores. Future randomized clinical trials are recommended to assess the optimal dose and route of administration of vitamin C.

## Citations

- MJ Rewhorn, AH Leung, et al. Incidence of Complex Regional Pain Syndrome after Foot and Ankle Surgery. *J Foot Ankle Surgery* 53 (2014) 256-258.
- SK Panchbavi, SG Trevino et al. The “Kick-Off” Position: A New Sign for Early Diagnosis of Complex Regional Pain Syndrome in the Leg.
- A Shah, JS Kirchner. Complex Regional Pain Syndrome. *Foot Ankle Clin N Am* 16 (2011) 351-366.
- HK Karn's-Schneider, MI Bodde, et al. Amputation for Long-Standing, Therapy Resistant Type I Complex Regional Pain Syndrome. *J Bone Joint Surg Am.* 2012;94: 2263-68.
- CJ Hogan, SR Hurwitz. Treatment of Complex Regional Pain Syndrome of the Lower Extremity
- N Shibuya, J M Humphers, et al. Efficacy and safety of High-dose Vitamin C on Complex Regional Pain Syndrome in Extremity Trauma and Surgery- Systematic Review and Meta-Analysis. *Journal Foot Ankle Surgery* 52 (2013), 62-66.
- I Seth, G Bulloch, et al. Effect of Perioperative Vitamin C on the Incidence of Complex Regional Pain Syndrome: A Systematic Review and Meta-Analysis. *Journal Foot Ankle Surg* 61 (2021) p. 748-754.

# ORTHOSPORTS



**NOTES:**



## **Sesamoids and accessory bones of the foot and ankle**

So-called because the ancient anatomist's thought that they looked like sesame seeds.

The sesamoids are almost invariably under the first metatarsal head though occasionally a sesamoid is absent and occasionally patients have sesamoids beneath all the lesser metatarsal heads.

Anatomical variations are common, approximately one third of patients have a sesamoid in more than one piece known as a "bipartite sesamoid". Bipartite sesamoids are more prone to injury and are not necessarily bilateral. If a sesamoid is bipartite it is usually the tibial sesamoid.

The sesamoid bone anatomically is in the tendon of the flexor hallucis brevis muscle. They are attached on the medial side to the abductor tendon and on the lateral side to the adductor tendon. There is also attachment to the plantar plate, intersesamoid ligament and the plantar aponeurosis. The tibial sesamoid is usually more distal and is usually larger.

There are many pathologies possible with sesamoids including hypertrophy, intractable plantar keratosis, bursitis, nerve compression, degenerative joint disease, subluxation, osteochondritis and fracture. Turf toe in athletes can involve sesamoid fracture.

The term sesamoiditis is often used in relation to sesamoids and I feel it is a term best avoided as it implies an "inflammation" and inflammation of the sesamoids is highly unusual.

In terms of imaging sesamoids always start with plain x-rays: a standing AP and lateral, oblique views and an axial radiograph will project the sesamoids away from the metatarsal head. If proximal migration of the sesamoids is suspected such as in a turf toe type injury then taking an x-ray of the normal side is very helpful.

Injuries to the articular cartilage, sesamoid ligaments as well as the plantar plate are best imaged with MRI scan. MRI scan is often used when a "turf toe" or sand toe is suspected. MRI must be of high detail read by a specialised radiologist. Bone scanning can be of some use and CT scanning must also be of high detail.

Often when a sesamoid collapses the question of osteonecrosis arises but I feel this situation is often due to trauma and that the sesamoid has merely fragmented.

Without surgery a sesamoid fracture can be treated in a walking boot or cast. Obviously the avoidance of impact is useful. An orthotic may be helpful but the orthotic must include deflection of pressure away from the sesamoid not merely an arch support. Occasionally taping the hallux in neutral or slight flexion will decrease the pressure on the sesamoid.

## Dr John Negrine

*M.B., B.S. (Syd), F.R.A.C.S. F.A. Ortho. A.*

*Adult Foot & Ankle Surgery*



In terms of surgical treatment: a keratosis beneath the sesamoid can be treated with shaving the sesamoid. In the right fracture in the right patient grafting a sesamoid can be effective.

When the sesamoid is excised an attempt must be made to repair the muscle and ligamentous structures somewhat analogous to repairing the quadriceps after removing a patella. Earlier studies suggested that up to 40% of sesamoidectomy patients had some residual symptoms. Repairing the structures will avoid a varus or valgus deformity of the toe.

Sesamoidectomy is the last resort.

### Accessory Ossicles:

Accessory ossicles around the foot and ankle are **common skeletal variations**. They are usually derived from the failure of union of secondary ossification centers adjacent to the main bone. They might be either adjacent to the main bone or separated.

Frequency of accessory ossicles:

- Os peroneum 26%
- Os trigonum 5 – 15%
- Os Vesalainum (0.1 – 5.9%)
- Os calcaneus secundarius (0.6 – 7%)
- Os intermetatarsium (1 -7%)
- Accessory navicular 4%
- Os subfibulare (0.2 – 2.1%)

They are of significance because they are frequently confused with fractures. Most are asymptomatic but occasionally following an injury the accessory ossicle may become symptomatic.

They often have interesting Latin names and identification and naming of them really impresses the patients most of whom have been told they have a fracture!

**Dr John Negrine**

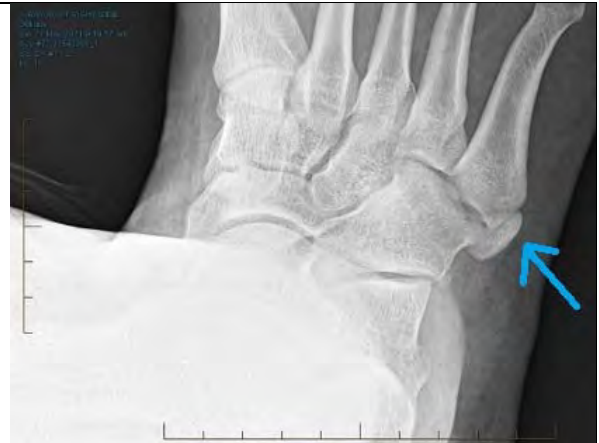*M.B., B.S. (Syd), F.R.A.C.S. F.A. Ortho. A.  
Adult Foot & Ankle Surgery*

In the last few months I have taken three examples from my patients to illustrate the point.

The first patient was a 16-year-old girl who injured her foot playing netball. She presented with pain and tenderness at the base of the fifth metatarsal and was diagnosed as a fracture.

Her x-rays however show a rounded ossicle at the base of the fifth metatarsal. This is an accessory bone known as the "os vesalainum" named after/by Andreas Vesalius the 16<sup>th</sup> century anatomist (recall that xray was not invented till 1895.)

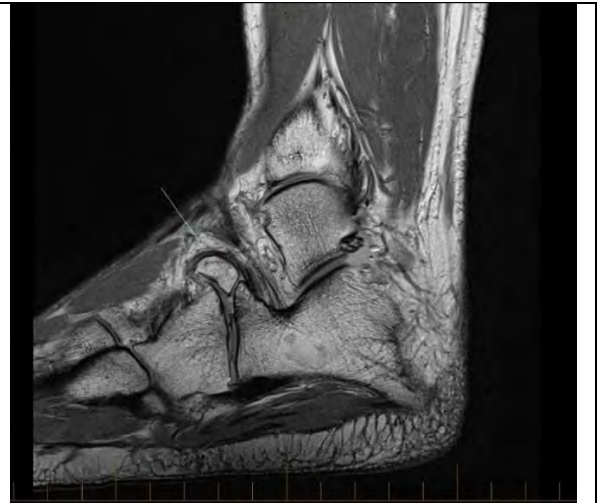
The ossicle is a failure of ossification of the apophysis (growth plate in traction) and is in the fibres of peroneus brevis. It will usually ossify by age 14 in females.



The second patient is a 40-year-old lady that has injured her ankle and experiences ongoing pain laterally.

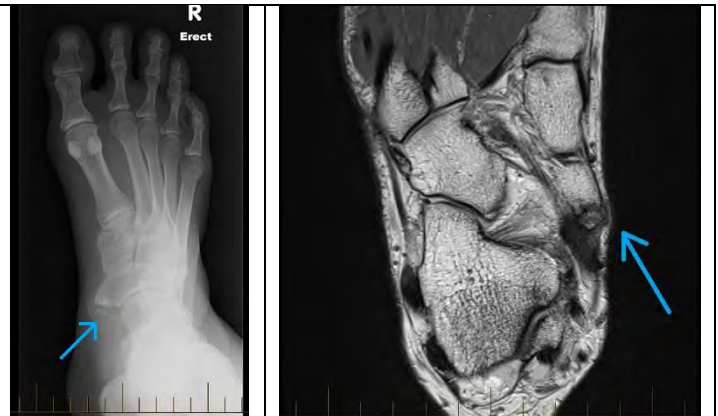Plain x-rays show a? Fracture of the anterior process of the calcaneus.

On MRI scan she has an accessory ossicle known as the "os calcaneus secundarius".



The third patient is a 32-year-old lady injured her ankle and presents with pain on the medial border of the foot.

Plain x-rays and an MRI scan clearly show an accessory navicular bone which is the site of her tenderness. Interestingly the accessory ossicle is better imaged on plain x-ray than MRI scan.



**Dr John Negrine**

*M.B., B.S. (Syd), F.R.A.C.S. F.A. Ortho. A.  
Adult Foot & Ankle Surgery*



Initial management for all these patients consisted of resting in a walking boot. When not settling excision of the accessory bone and usually repair of the adjacent tendon into the bone is the treatment of choice.

**Final note:**

Don't over stretch Achilles tendon repairs, they all lengthen anyway.

**References:**

Comparison of Tendon Lengthening with Traditional vs. Accelerated Rehab Following Achilles Tendon Repair: A Randomized Controlled Trial

Am.J Sports Med 48 (7) 1720 2020 Okoroha et. al

John P. Negrine FRACS Sydney October 2022

**NOTES:**

## Imaging in Musculoskeletal Assessment

The topic of imaging in musculoskeletal medicine is vast and not likely to be fully covered in this article. It is however important to discuss the various indications for modalities and where they fit in the diagnosis of your clinic patients. We now live in an age where most patients are well informed and often will present requesting an MRI scan as an initial step in management. Whilst at times this may be appropriate often there may be another test which is more appropriate. We know there will be a cost to the patient and community in terms of money and time to obtain the test. Medicare spends millions of dollars every year on subsidizing the costs of investigations, so it is important to order them in the most effective fashion possible. This article will discuss some of the principles of ordering investigations appropriately.

1. The investigation should change or influence your management.

This is an important concept to ponder anytime you consider getting any test performed. Is the test worth getting and will it change our management? The basis for treating any musculoskeletal condition is founded on accurate diagnosis. Any investigation incurs not only cost (patient/Medicare), but also a time cost to that person, so it needs to be helpful to the treatment of that patient. There may also be a potential for a false positive result which may lead to the need for further investigation and unnecessary treatment. Practitioners must be prepared to manage based on the test result, or there is little point proceeding with the investigation.

2. The investigation should be the most appropriate one to diagnose the issue based on clinical (history and examination) presentation.

There should be a consideration of all manner of imaging relevant to the patient before a modality is chosen. This will be driven by the history, but more importantly the examination. The test should always try to confirm the clinical suspicion, not make the diagnosis on its own.

3. The investigation should be the simplest (and cheapest) one to confirm the clinical suspicion.

Cost is important when ordering investigations. An X-ray is a much simpler and cheaper test than an MRI, and in many cases may provide all the information that is required to make a diagnosis, without requiring a more 'high-powered' scan.

### **X-ray**

There is never a reason to not investigate a musculoskeletal condition initially with a plain X-ray. An X-ray will convey important information with respect to bone and joint issues, particularly osteoarthritis, and assess for the unexpected, such as a cancer. Stress or weight-bearing views may also provide important information in joint instability, such as in a Lis Franc sprain in the foot. If a patient has been treated a few times for any issue and progress is not being made, then a plain X-ray should be mandatory before continuing further physical treatment. A plain X-ray is always helpful, even if normal, and should be provided prior to any specialist appointment either from the referring physio or GP.

## **Dr Paul Annett**

*M.B.,B.S.(Hons I) FACSP,*

*Sport & Exercise Medicine Physician*



### **Ultrasound**

As a rule, ultrasound is an overutilized modality. Whilst it can provide information in certain conditions, a proportion of these can be diagnosed purely on clinical grounds, such as tennis elbow or plantar fasciitis. The difficulty with US and tendinopathy, especially with increasing age, is the likelihood of age-related degenerative changes that are not always clinically significant. US also lacks the accuracy of MRI, especially with deeper tissue structures, and can be heavily dependent on not only the operator and reporter, but also the quality of the machine. One advantage of US can be the dynamic nature of the test, allowing assessment of the abnormality with motion in real time. An US should always be ordered in association with a plain X-ray of the corresponding area.

### **CT scan**

CT scanning is most useful for assessment of bony structures and plays little role for soft tissue injury. It can be helpful for diagnosis of missed fractures as an extension of plain X-ray when there may be some doubt on the extent of injury. It offers little above plain films for the diagnosis of osteoarthritis. A downside of CT scanning is the radiation dose, which is significant, especially if performed axially. This is an issue with lumbar scans ordered without a clear history of radiculopathy, which often occurs in the management of lower back pain.

### **Nuclear medicine (Bone scan)**

Whilst nuclear medicine imaging has been replaced in many areas by MRI, it still has a role to play in certain circumstances. Its main advantage is sensitivity, but not necessarily specificity. It may be helpful in diagnosing missed fractures or stress fractures may, but MRI is generally as sensitive for this purpose. With multiple joint issues bone scanning also has the ability to look at the 'whole body' at the one time, with one scan. Bone scanning also has the advantage over other modalities in localizing specific pathology in the presence of wide-spread degenerative disease. This may be helpful with generalized facet joint arthrosis in lumbar spondylosis. It can allow local treatment such as cortisone injection to be performed with improved accuracy.

### **MRI**

MRI is clearly the pinnacle of imaging. It has been described by radiologists as the 'test of truth' because there is little that will not be picked up by this modality. In many ways this can be to its detriment, particularly in the older patient, where multiple age-related changes need to be correlated to clinical findings. As such the interpretation of the MRI is just as important as the scan findings themselves. Abnormalities such as labral tearing in the hip, meniscal tearing in the knee and disc desiccation in the lumbar spine do become more common with age and are often incidental findings not relevant to the clinical presentation. MR's strength is with soft tissue injury and its weakness is with bony injury and particularly fractures, where CT is superior. It is, however, quite sensitive in detecting bone marrow oedema or 'bone-bruising'.

The major downside with MRI scanning is cost. An MRI is many times more expensive than a plain X-ray and some justification needs to be made for its use from a health economic point of view. It is most beneficial when other modalities have failed to provide an accurate diagnosis or there is 'diagnostic doubt'.

## **Common Imaging Issues**

### **1. Ultrasound of the shoulder without a plain X-ray.**

The shoulder is a complex joint with multiple potential causes of pain that may not be related to sub-acromial bursitis, which is a very common finding on US, and often not the clinical issue. X-Ray can adequately assess for osteoarthritis of the AC or glenohumeral joints, acromial morphology, superior humeral head migration and tumours. As previously mentioned, an ultrasound should not be performed without an X-ray of the corresponding body area.

Sub-acromial bursitis is a very common finding on ultrasound. This is a good example of when reliance on imaging over clinical examination can cause issues. Patients may be sent for sub-acromial cortisone injections based on the ultrasound findings when the clinical diagnosis shows restricted shoulder motion, more consistent with an adhesive capsulitis.

### **2. Ultrasound of the knee**

As a modality around the knee US does have limited indications. It will not diagnose meniscal tears or osteoarthritis. Knee effusions should be detected clinically, as should knee instability. Baker's cysts are generally an incidental finding related to osteoarthritic change. If there are concerns about intra-articular pathology in the knee and X-rays are normal, then an MRI is the most appropriate test.

### **3. Ultrasound of the hip without a plain x-ray**

As with the shoulder, an X-ray of the hip should be a mandatory test if an ultrasound is performed. The most common cause of groin pain, particularly in the older patient, is underlying hip joint osteoarthritis. This will not be diagnosed on ultrasound alone and should be apparent on a hip and pelvis X-ray.

### **4. CT scan of the lumbar spine**

As a rule, CT scans are an over ordered investigation for lower back pain, particularly by general practitioners. In simple non-radicular back pain often no imaging is required, or at best a plain X-ray if symptoms are not improving after appropriate treatment, or there are any 'red-flags'. Plain X-ray will exclude any sinister pathology and can assess for disc desiccation and facet arthrosis. CT scanning is indicated in radicular pain, but does lack accuracy in comparison to MRI, which should be the investigation of choice. It also carries a significant radiation dose, which MRI does not.



# ORTHOSPORTS



**NOTES:**

**Dr Samya Lakis**  
*M.B.B.S., F.R.A.C.S. (Ortho.)*  
*Spinal & Paediatric Orthopaedic Surgery*




## Notes

## Paediatric ACL Injuries

**Paediatric ACL injuries**  
 Dr Christopher Spelman


**Key history points**

- Mechanism of injury
  - Non-contact pivot, or hyperextension injury
- Early haemarthrosis
- Ability to weight bear post.
- Previous knee injuries
- Locking/catching/clicking
  - Meniscal pathology/OCD
- Age, menarche, growth velocity



**ACL injuries**


- Increasing incidence with competitive sport
- F:M 4:1
- Surgical management depends on remaining growth



A complete tear of the ACL

**Knee Examination**

- Alignment
  - Valgus knee alignment predisposes to ACL tear
- Gait
  - Need for brace/walking aids
- Effusion/Haemarthrosis
- Palpation
- Range of motion
- Clicking/Catching/ Locking



Normal      Valgus      Knock knees (valgus)

**ACL Injuries – History and Examination**

*No isolated question, clinical test or imaging modality can accurately diagnose an ACL injury every time*


**Knee Examination – Special Tests**

- Always compare to contralateral side
- Children have more joint laxity than adults, difference between sides is more important than absolute figures

### Knee Examination – Special Tests

**Anterior drawer**


- Hip flexed to 45°
- Knee flexed to 90°
- Positive if >5mm difference to contralateral side
- 22.2% sensitivity and 95% specificity within 2 weeks
- 40.9% sensitivity and 98.4% specificity after 2 weeks



### Knee Examination – Special Tests

**Varus Stress Test (LCL)**


- Knee flexed to 30°
- Knee full extension
  - ITB, Biceps Femoris, Arcuate complex, PLC
- Sensitivity 25%



### Knee Examination – Special Tests

**Lachman's Test**


- Knee bent 20-30°
- Positive if >2mm difference to contralateral side
- 77.7% sensitivity and >95% specificity with 2 weeks
- 84.8% sensitivity and >95% specificity after 2 weeks



### Knee Examination – Special Tests

**Pivot Shift Test**


- Knee in full extension
- Foot in internal rotation
- Axial load, valgus force
- Slowly bend knee, as ITB passes over femoral condyle it will reduce the subluxed tibia
- 35% sensitivity and 99% specificity with 2 weeks



### Knee Examination – Special Tests

**Valgus Stress Test (MCL)**

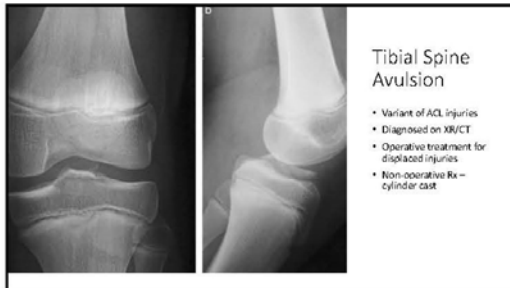- Knee flexed to 30°
  - Isolates MCL
- Knee full extension
  - MCL, capsule, ACL, PCL
- 86%-95% sensitive



### ACL Injuries - Investigation

- Plain XRs – Always required
- MRI – Useful\*
- CT – Bony injuries
- EOS – All operative cases

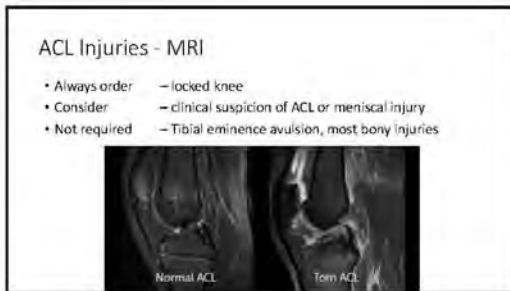



**ACL Injuries – Indications for surgery**

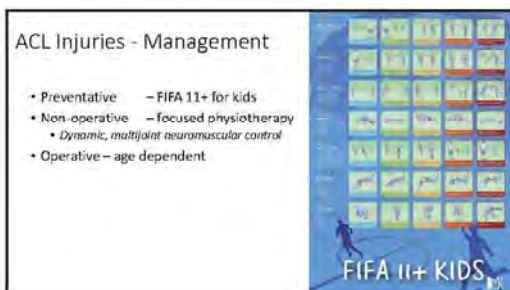1. The child has repairable associated injuries that require surgery (eg, bucket-handle meniscus tear, repairable meniscal lesion or osteochondral defect).
2. The child has recurrent, symptomatic knee giving way after completing high-quality rehabilitation.
3. The child experiences unacceptable participation restrictions (ie, an unacceptable modification of activity level to avoid knee giving way).

IOC consensus statement 2018 Paediatric ACL injuries




**ACL Injuries – Natural History**

- ACL injuries have low rates of return to competitive sport
- No long term studies on OA (Adults symptomatic OA in 10 years)
- High rates of subsequent meniscal injuries (2%/month)




**ACL Injuries – Associated injuries**

- Meniscal tear 58%
  - increase by 12% for every 2 BMI points over 25
  - increase by 16% for every year of age over 10



**Rates of Concomitant Meniscal Tears in Pediatric Patients With Anterior Cruciate Ligament Injuries Increase With Age and Body Mass Index**

Journal of Pediatric Orthopaedics, Volume 35, Number 10, October 2015

### ACL Injuries - Diagnosis

**Table 1** Diagnostic Accuracy of clinical examination and MRI in intra-articular knee disorders (adapted from Kocher et al.<sup>1</sup>)

Diagnosis	Sensitivity (%)			Specificity (%)			Positive predictive value (%)			Negative predictive value (%)		
	Clinical examination	MRI	P value	Clinical examination	MRI	P value	Clinical examination	MRI	Clinical examination	MRI	P value	
ACL tear	85.0	95.0	0.05	96.6	98.9	0.07	93.0	98.6	97.8	97.7	0.01	
Medial meniscus tear	62.1	79.3	0.15	88.3	92.6	0.01	54.5	88.3	91.8	98.8	0.00	
Lateral meniscus tear	53.0	68.7	0.24	89.2	82.6	0.21	34.9	85.1	64.5	95.7	0.01	

1. Kocher M, Sckanawaj C, Gombatto B, et al. (2004) A comparison of the accuracy of clinical examination and magnetic resonance imaging in the diagnosis of intra-articular knee disorders in children and adolescents. Am J Sports Med 32(12):1462-1472. doi:10.1177/0097130404263828

### ACL Injuries – Physeal Sparing

- Boys 10-14, Girls 10-12
- Drill holes avoiding physis
- Higher re-rupture rate than anatomical ACL reconstruction

A. Anterior view  
B. Lateral view

### Surgical Management

- Based on skeletal age and associated injuries

### ACL Injuries – Transphyseal Reconstruction

- Within 2 years of skeletal maturity
- Similar to adult ACL recon
- Steeper tunnels
- Suspensory fixation
- Hamstrings graft

A. Anterior view  
B. Lateral view

### ACL Injuries – Over the top reconstruction

- Young children
- Non-anatomic
- Strip of ITB re-routed through the knee and fixed to proximal tibia

A. Anterior view  
B. Lateral view

### ACL Injuries – Technique points:

- Minimise growth disturbance
- Avoid the perichondral ring
- Central, steep tunnels

### ACL Injuries – Surgical risks

- Growth disturbance
- Re-injury (ipsilateral 13%, contralateral 14%)
- Stiffness
- Infection



### Post-op

- Swelling control, ice packs
- ROM focussing on full extension as 1<sup>st</sup> goal
- Gentle cycling from 6 weeks
  - Risk of graft stretching before 12 weeks
- Jogging from 4 months
- Return to sport minimum 12 months
- Triple hop >90% contralateral
- Muscle strength >90% contralateral

### Take home points

- Always get an XR
- Clinical examination is important, but less reliable than adults
- MRI better to exclude pathology rather than diagnose
- Surgical management based on remaining growth

## Dual Mobility Hip Replacements

Total Hip Replacement has been with us for more than 60 years. The principle of replacing the natural joint with an artificial prosthesis has remained the same. At a glance the current implants may resemble Charnley's original prosthesis as ball and socket joints, but much has changed in terms of materials and methods.

In a previous Orthopaedic Update, I made mention of the Australian National Joint Replacement Registry. Much of our current practice is based on collective experience and our registry, which is in its 22<sup>nd</sup> year and has more than 800 000 hip replacements on record. The registry captured data on patients, prostheses, surgeons, and methods of implantation. The registry produces a detailed annual report. Any revision procedure is counted as a failure of the implant, even if in cases of infection or fracture of a bone the implant itself has not failed.

Data from our registry, and from similar registries around the world have changed our practice. Broad guidelines have evolved and manufacturers as well as surgeons have taken notice. Whilst non-cemented implants perform well in younger patients with good bone stock, those over the age of 70 do better with cemented femoral prostheses, most of which have a polished double taper stem. Virtually all polyethylene is now crosslinked, and the registry clearly shows that bigger femoral heads are more stable.

In some countries, like France, dual mobility hip replacements have been used for a number of years, but in Australia this type of implant is still relatively new. Dual mobility is like a cup within a cup, so that there are two articulating surfaces. The inner articulating cup becomes the outer layer of the head, thus increasing the size of the femoral head. Typically, a diameter of 40 to 42.5mm can be achieved, which is believed to increase the stability of the implant.

Compared to so called conventional total hip replacements, the data on dual mobility implants in our registry is still small. Whilst we are currently doing comparative studies, it will take a few more years to deliver proof of whether dual mobility implants perform better or not. The theoretical advantages of larger femoral heads, as well as the experience in other countries, make the use of dual mobility hip replacement attractive in certain groups of patients.

Dislocation is one of the complications of total hip replacement. The risk of dislocation is increased in patients who had a hip replacement for fracture of the femoral neck. Dislocation is also more common in patients with cognitive and compliance issues. Of particular interest are also patients who have had a spinal fusion. As the spine stiffens, flexion at the hip increases, and so does the risk of dislocation. Paradoxically dual mobility increases stability and reduces the risk of dislocation.

The surgery for dual mobility prostheses is identical to conventional hip replacement. A standard acetabular cup is implanted. Depending on the size of the cup a suitable chrome cobalt liner is then inserted. The size of the cup determines the size of the dual mobility head. The femoral stem is implanted independent of the articular device. Dual mobility heads can be attached to almost all types of femoral stems.



Post-operative care for patients with dual mobility prostheses is identical to other hip replacements. Patients can mobilize as soon as their general condition allows. So called Hip Precautions are not generally required. Patients occasionally hear a little click as the neck of the femoral stem hits the articulating polyethylene shell, but the patient is not otherwise aware of the dual mobility implant.

The theoretical downside of dual mobility implants is polyethylene wear. There are two articulating surfaces, which theoretically increases the chances of creating polyethylene wear particles, which may then lead to aseptic loosening and failure of the prosthesis. Highly crosslinked polyethylene is less likely to wear, and most dual mobility implants are currently used for elderly patients, who are unlikely to wear out their implants.

In addition to current comparative studies of dual mobility implants with conventional hip replacements, the NJRR will record the performance of dual mobility implants and it will be interesting to see how they perform on the long run. On the short term at least, the risk of dislocation seems to be reduced.



# ORTHOSPORTS

**Thank you to our 2022 Sponsor**

---



**CASTLEREAGH  
IMAGING**

---



**ILLAWARRA  
RADIOLOGY GROUP**



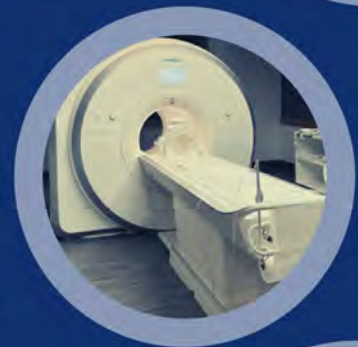# THE LEADERS IN DIAGNOSTIC IMAGING

Castlereagh Imaging is committed to providing excellence in all imaging modalities with a courteous, personalised service for our patients and referring Doctors.




## OUR TEAM OF SPECIALISTS COVERS ALL IMAGING MODALITIES

- MRI
- CT
- PET CT
- NUCLEAR MEDICINE
- X-RAY
- DEXA
- EOS
- ULTRASOUND
- INTERVENTIONAL PROCEDURES
- 3D MAMMOGRAPHY



CONTACT US VIA PHONE OR EMAIL FOR MORE INFORMATION

 1300 669 727

 [clientservices@casimaging.com.au](mailto:clientservices@casimaging.com.au)

**Dr Doron Sher**

*M.B., B.S. (NSW), M.Biomed.E.,  
F.R.A.C.S. (Ortho.)  
Knee, Elbow, Shoulder Surgery*

**Dr Paul Mason**

*FACSEP, M.B.B.S.(Hons),  
Bachelor Physiotherapy, Master Occupational Health  
Sport & Exercise Medicine Specialist*



## **Knee Joint Examination**

### **Notes:**

## **Dr Ivan Popoff**

*BPhEd (1986), MBChB (1991), F.R.A.C.S. (Ortho.)  
Shoulder, Knee and Elbow Surgery*



# **Management of difficult rotator cuff tears**

## **Natural History of Rotator Cuff tears**

- Tear Progression
- Tendon Degeneration
- Fatty Atrophy
- Fixed Retaction
- Rotator Cuff Arthropathy

## **Factors Affecting Cuff Repairability**

- Time between tear and definitive treatment- Major factor
- Size of tear
- Retaction - fixed
- Tendon Quality
- Fatty Atrophy
- Adhesive Capsulitis

## **Factors Affecting Healing**

- Age - controversial
- Time to surgery
- Tendon- biological healing potential
- Smoking
- Corticosteroids
- Surgical technique
- General Health - D.M., Hyperlipidaemia

## **Dr Ivan Popoff**

*BPhEd (1986), MBChB (1991), F.R.A.C.S. (Ortho.)  
Shoulder, Knee and Elbow Surgery*



### **Risk Factors for Repair failure**

- All of the above
- Compliance
  - patient
  - physiotherapist

### **Success Rates of Surgery**

Massive Retracted Cuff tears requiring interval slides and revision rotator cuff surgery can be as low or lower than 50%

### **Improving Outcomes**

- Supplementation with Human Allograft either as a patch to reinforce a repair or as a superior capsular reconstruction increases success rates to around 75%
- Supplementation with biological agents- PRP, PDGF, Fibrin patch / bone marrow aspirate
- Autograft - tensor fascia lata
  - -LHB
- Hybrid Graft - BioRez- PLLA + bovine derived collagen
- Tendon Transfers
  - Lat. Dorsi -posterior /superior tears, sub scap
  - Teres major- posterior/superior
  - TM and LD
  - Lower Trapezius (requires TA allograft)- post/sup
  - Pectoralis Major- sub scap

## Dr John P Best

B Med, Dip Sports Med (London), FACSP, FFSEM  
Sport & Exercise Medicine Physician



## Assessing Rotator Cuff Deficiency

It is not unusual to see patients with shoulder dysfunction, generally over the age of 50 years, who attend with a shoulder ultrasound report stating .. *“there is a degenerative tear of the supraspinatus tendon at its insertion with a partial tear of infraspinatus; the appearance suggests tendinopathy. There is fluid within the subacromial bursa with features of impingement”*.

Many of these patients are confused about the pathology – is it a tear that needs an operation? How can exercises help heal a tear? Do I have two tears? And so on.

This presentation is intended to offer some clinical suggestions to assist in your assessment of the rotator cuff and in particular to assess its integrity.

### Demographic and cultural considerations

Our ageing population who are active creates a scenario where many patients will develop shoulder pain with physical activity. The Australian Bureau of Statistics reported that in 2021 people aged 65 or over outnumbered those under 15, and by 2051 nearly one quarter of the population will be 65 years or older.

Bearing in mind that ultrasound tendon changes of the rotator cuff tendon are frequently ‘age-appropriate’ and asymptomatic, it is useful to consider which of our patients will be in the better outcome category and which will be in the ‘more difficult’ outcome category.

Two cases will be presented to demonstrate a clinical approach to assess the integrity of the rotator cuff.

### Clinical Considerations

- History

Acute trauma followed by weakness is a poorer prognostic sign and is more suggestive of a full thickness rotator cuff tear. If this has been associated with persistent night pain and significant loss of active movement this is a poorer prognostic sign. An early response to NSAIDs or simple analgesics post injury is a good prognostic sign. Elimination of pain with a sub-acromial corticosteroid and local anaesthetic injection is generally a good prognostic sign

Please don't forget your ‘red flags’ – night pain, fever and neurological symptoms. All patients attending for treatment with night pain, trauma and movement restriction require an x-ray

- Examination

The poorer prognostic features include weakness in more than one plane (i.e. forward elevation and external rotation). A reduction in impingement features with scapular retraction is a good prognostic sign. It suggests that re-orientation of the acromion (scapular) with active retraction should offer some success with exercise therapy.

## **Dr John P Best**

*B Med, Dip Sports Med (London), FACSP, FFSEM  
Sport & Exercise Medicine Physician*



It may be difficult to assess rotator cuff integrity in the presence of subacromial bursitis. Therefore, assessing the rotator cuff in non-impingement positions is valuable. For the subscapularis this may be the 'lift-off test' and infraspinatus may be tested with ER in standing (arm by side). The supraspinatus has typically been tested as an 'empty can', 'Jobe' or 'drop arm' tests. This can be a challenge with bursal impingement and pain inhibition can interfere with these signs. I will suggest that testing the supraspinatus from a position of prone shoulder extension is worth considering. This will be demonstrated.

### **The Role of Imaging**

The poorer prognostic features on imaging relate to bone morphology, tendon tear size and the presence of muscle atrophy. Significant subacromial osteophytes (spurring) with compression into the bursa and rotator cuff frequently creates ongoing impingement. Patients tend to be very impressed if you can show these imaging signs to them. Tendon tearing is best seen with Magnetic Resonance Imaging, in particular with arthrography (MRI Arthrogram). The site and size of the tear is easily seen. In addition the extent of muscle atrophy is a prognostic feature. The other advantage of X-ray and MRI is to identify the presence of glenohumeral osteoarthritis, which can affect the recovery time-frames.

#### References:

A Systematic Approach to MRI Interpretation of sport Medicine Injuries to the Shoulder.  
Sanders et al, The American Jnl of Sp Med., Vol 33, 7: p1088-1105

Shoulder Impingement Syndrome

Julie A. Creech; Sabrina Silver. April 21, 2022.

<https://www.ncbi.nlm.nih.gov/books/NBK554518/> (National Library of Medicine, USA)



# ORTHOSPORTS



**NOTES:**

## Shoulder Instability

We know that younger patients and those doing sport that dislocate their shoulder are likely to do so again. Having more than 2 dislocations leads to a higher likelihood of arthritis developing in the shoulder. While it is generally clear that a patient requires surgical stabilisation of the shoulder it can be less clear which operation is best for them. In broad terms the procedure can be performed **arthroscopically** or **open**. There are advantages and disadvantages to both approaches.

**Arthroscopically** you can achieve a labral repair, capsular plication, Remplissage (suturing the infraspinatus into the Hill Sachs lesion) or a combination of these.

**Open** surgery can take the form of a labral repair, capsular shift or a bone transfer procedure (whether it be locally like a Latarjet or remotely like an Iliac crest bone transfer).

**Arthroscopic stabilisation** of the shoulder has a very low complication rate with a very high level of return to sport (close to 90%). *It is the operation of choice for most people who dislocate their shoulder.*

The results of arthroscopic surgery are much worse in contact athletes so my treatment paradigm is broadly divided into patients who participate in contact sports (Rugby, AFL, Boxing, Basketball, Ice Hockey etc) and those who do not. The exception to this is a very high level contact athlete in the early part of their season.

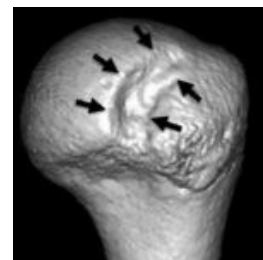
Re-dislocation rates after arthroscopic surgery are as low as 4% and as high as 25% depending on the individual patient. The re-dislocation rate of an arthroscopic stabilisation depends a great deal on which sport the person returns to, with a higher percentage of re-dislocation in collision athletes and younger patients (under the age of 18). The failure rates are also higher in the presence of a Bony Bankart lesion, ALPSA lesion and significant Hill Sachs lesion. Certain operations are not safely performed arthroscopically, such as a HAGL repair.

**Open Surgery:** If the patient is likely to re-dislocate with an arthroscopic operation we then change to performing open surgery for them. The next decision is whether to perform an open capsular shift or a bone transfer operation.

The presence of bone loss is a well-known risk factor for failure of shoulder stabilisation surgery. Although both humeral and glenoid-sided defects have been identified as risk factors for failure, the literature has generally treated these contributions independently. The first description of the dynamic interaction between the two was called an engaging **Hill-Sachs** lesion. We have now taken this further and take into account both glenoid bone loss and the size of the Hill-Sachs lesion.

### Definitions

Bone loss of the humeral head is known as a **Hill-Sachs lesion** (HSL). This is a compression fracture of the humeral head caused by the anterior rim of the glenoid when the humeral head is dislocated anteriorly in front of the glenoid (The humeral head is softer than the glenoid). HSLs are seen after two thirds of initial dislocations and 90% of recurrent dislocations.



The Hill Sachs Lesion  
seen on a 3D CT

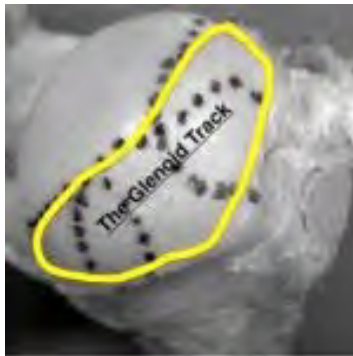
**Dr Doron Sher**

M.B., B.S. (NSW), M.Biomed.E., F.R.A.C.S. (Ortho.)  
 Knee, Elbow, Shoulder Surgery

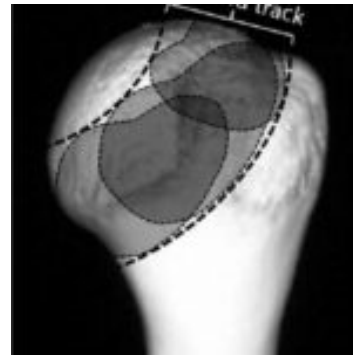


Bone loss of the glenoid is known as a **Bony Bankart** lesion. 80% of patients with anterior instability have both Hill-Sachs and glenoid bone lesions, called a 'bipolar lesion'.

As your arm is moved away from your side the humeral head rotates and glides on the glenoid. Only a small segment of the humeral head is in contact with the glenoid at any one time. The pathway defined by this contact between the humeral head and the glenoid is called the '**glenoid track**'. The width of the glenoid track (defined as the distance between the medial margin of the glenoid track and the medial margin of the footprint of the rotator cuff) is about 84% of the glenoid width.



The yellow line shows the contact area between the humeral head and the glenoid as the arm is moved through a range of motion



The glenoid track on the posterior aspect of the humeral head shown on a 3D CT scan with the glenoid extracted from the image

The term engagement refers to when the Hill Sachs lesion slips off the edge of the glenoid and the humeral head dislocates from the glenoid.




Image shows the blue area remaining in contact with the glenoid despite having some bone loss on the humeral head.

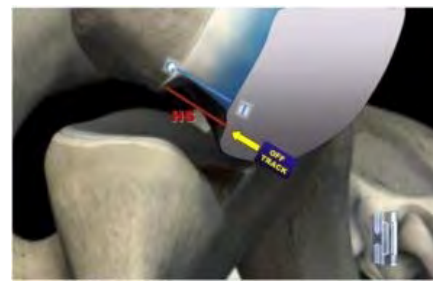
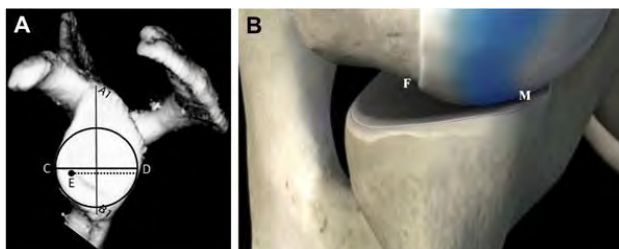


Image shows the humeral head dislocated because the blue area slips off the front of the glenoid.

If the HSL stays on the glenoid track (known as an **on-track** lesion) it does not engage (the humeral head does not slip off the glenoid) and therefore the shoulder does not dislocate.



No bone loss - on track shoulder  
 - The blue on the humeral head indicates the location of the glenoid track which equates to yellow line on the previous image

**Dr Doron Sher**

M.B., B.S. (NSW), M.Biomed.E., F.R.A.C.S. (Ortho.)  
Knee, Elbow, Shoulder Surgery

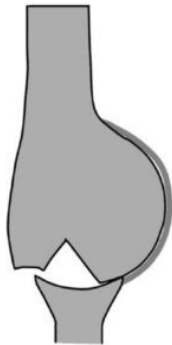


Diagram of an on track Hill Sachs Defect with a stable shoulder

On the other hand, a HSL, which is out of the glenoid track (**off-track** lesion), has a risk of engagement and dislocation.

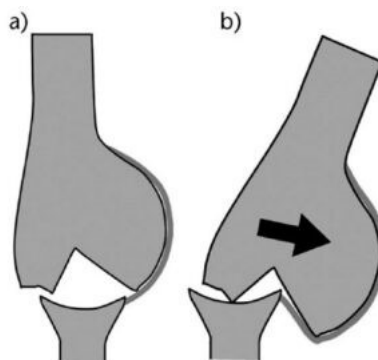
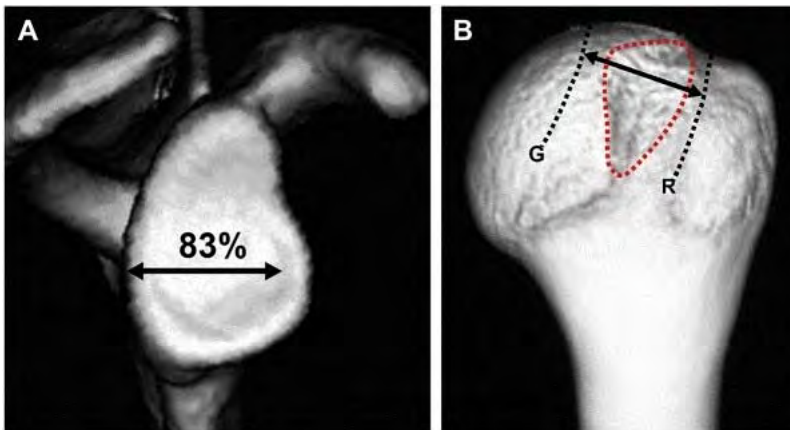


Diagram of an off track lesion which allows the shoulder to dislocate

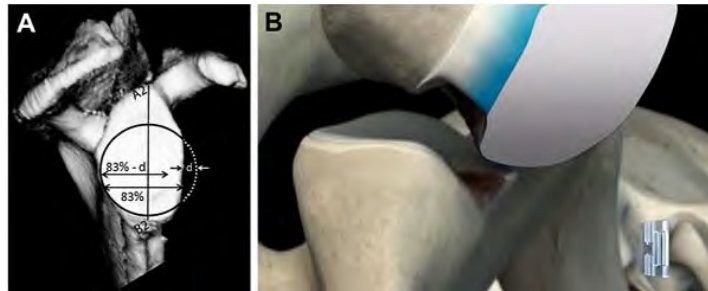


The red dots show that the Hill Sachs lesion is completely within the glenoid track (between R and G) meaning a stable or on track lesion

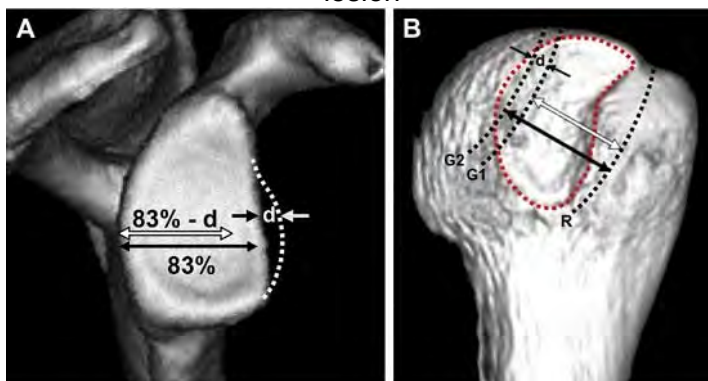
If there is less glenoid bone then the track available for the humeral head to follow is smaller. This requires an adjustment of the way the glenoid track is calculated (see below).

**Calculations**

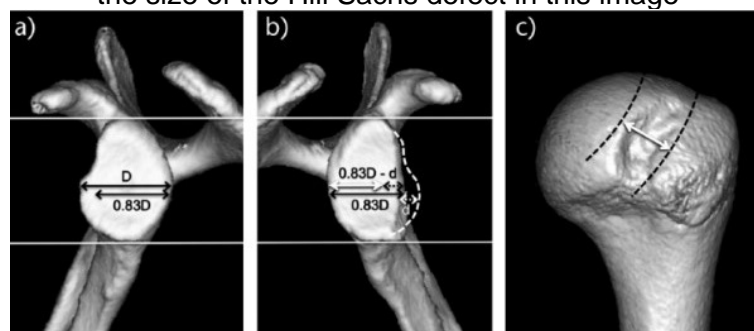
At this point things become a little more tedious because the actual calculation requires measurements and then some simple mathematical calculations. Currently the most accurate measurements are made from 3D CT scans. MRI scanning is catching up but is not as good for visualising bone loss as CT scanning is. The concept is a little easier to understand by going through the images below but: When there is no glenoid defect, the width of the glenoid track is 83% of the glenoid width. When there is a bony defect at the anterior rim of the glenoid, the defect width should be subtracted from the 83% length to obtain a true width of the glenoid track.



How to calculate the glenoid track from the 3D CT scan of the glenoid and in this case an off track lesion



The track measurement changes from G2 to G1 when there is glenoid bone loss. The red dots show the size of the Hill Sachs defect in this image



Measuring to see if you are on track or off track

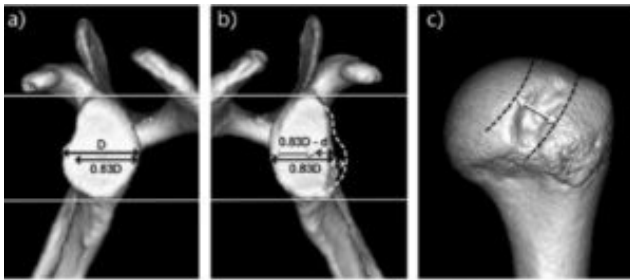
If the medial margin of a Hill-Sachs lesion is more medial than the glenoid track, standard stabilization procedures such as Bankart repair are unlikely to restore the shoulder stability.

**Imaging**

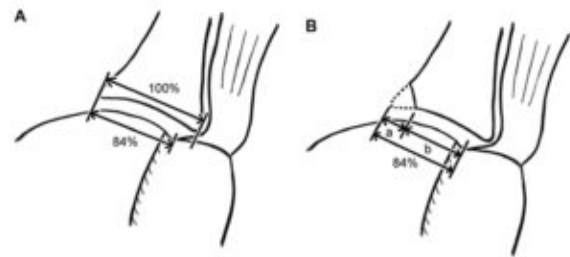
The actual imaging used is very important. You must have an 'en face' view of the glenoid which means you are looking directly at the glenoid on a 3D reconstruction image. This allows measurement of the glenoid width by several methods, all of which work fairly well. The other view required is posterior view of the humeral head on a 3D CT as well.

**How to calculate glenoid track**

- 1. Measure the glenoid:** The first measurement to do is that of the glenoid {D} (either using the other shoulder from the CT scan or using a ‘best fit’ method which allows you to estimate it using a circle). You then calculate 83% of that number.
- 2. Subtract the defect if present:** If there is a bony defect of the glenoid, the defect width ‘d’ needs to be subtracted from the 84% value (0.84D) to obtain the true width of the glenoid track (0.83D – d).
- 3. Measure the humeral head:** Apply this width (0.83D – d) to the posterior view of the humeral head.
- 4. Decide if ‘on’ or ‘off’ track**



Measuring to see if you are on track or off track



Diagrams showing why the glenoid track changes with glenoid bone loss reducing from a to b

**Table 1.** How to Determine Whether Hill-Sachs Lesion Is “On Track” or “Off Track”

- 
- 1. Measure the diameter (D) of the inferior glenoid, either by arthroscopy or from 3D CT scan.
  - 2. Determine the width of the anterior glenoid bone loss (d).
  - 3. Calculate the width of the glenoid track (GT) by the following formula:  $GT = 0.83 D - d$ .
  - 4. Calculate the width of the HSI, which is the width of the Hill-Sachs lesion (HS) plus the width of the bone bridge (BB) between the rotator cuff attachments and the lateral aspect of the Hill-Sachs lesion:  $HSI = HS + BB$ .
  - 5. If  $HSI > GT$ , the HS is off track, or engaging. If  $HSI < GT$ , the HS is on track, or non-engaging.
- 

**Outcome options**

If the medial margin of the HSL stays within the glenoid track, there is no risk that this HSL engages with the anterior rim of the glenoid.

If the HSL extends more medially over the medial margin of the glenoid track, there is a risk of engagement.

These used to be called ‘non-engaging HSL’ and ‘engaging HSL’ but this has been replaced by the concept of on or off track.

## Dr Doron Sher

M.B., B.S. (NSW), M.Biomed.E., F.R.A.C.S. (Ortho.)

*Knee, Elbow, Shoulder Surgery*



### Treatment

Tightening the anterior soft-tissue structures limits external rotation and horizontal extension, making the glenoid track shift medially and superiorly. This shift covers the entire Hill-Sachs lesion and thus prevents engagement of the lesions (that is why an arthroscopic stabilisation is still the most common operation performed).

For off-track lesions, bone transfer surgery is most commonly performed (although this operation has a higher complication rate and creates problems in the future if the patient needs a shoulder replacement). In some situations an open capsular shift or adding a remplissage to the operation may be used, depending upon the glenoid defect size and the risk of recurrence (such as involvement in collision sports).

In the rare situation that there is significant glenoid bone loss and a large Hill Sachs lesion treatment of both lesions might be required.

**Laterjet:** The Laterjet procedure (coracoid bone transfer) was designed to treat patients with significant glenoid bone loss and shoulder instability.

Recently there has been a considerable shift towards doing a Laterjet procedure as the patient's first operation, even without bone loss. While this operation will certainly stop the shoulder from physically dislocating it does not necessarily cure the patient's sensation of the shoulder moving excessively because it does not address the issue of capsular laxity that caused the problem in the first place. In many cases this operation is being used for contact athletes, despite them not having any significant bone loss (which is not what the operation was originally designed for).

The complication rate for a Laterjet procedure has been documented to be far higher than an open capsular shift. Complication rates of 12% (and higher) are often quoted, varying from permanent nerve injury, through failure to heal of the bone and hardware complications such as damage to the humeral head from the screws. If this operation fails there are not many options left to salvage the shoulder.

Over the last few years it has become clear that if a Laterjet is performed where the patient does not have any bone loss then the bone graft will reabsorb and disappear because it is not being loaded. This leaves the screws used to hold it in place very prominent and likely to create damage to the humeral head.

### **Open Stabilisation**

An open stabilisation and capsular shift does have the disadvantage of taking down and then repairing the subscapularis muscle. It is possible to create some fatty degeneration in the subscapularis muscle belly but this does not seem to create much in the way of functional limitation for the patient.

The advantage of this operation is that allows the labrum to be repaired and the stretched out capsule to be tightened. The success rate of this operation is very high with a very low re-dislocation rate, even in contact athletes.

### **Decision Making:**

The factors to consider are:

- Age
- Contact athlete
- Labral Tear
- SLAP lesion alone
- Capsular stretch without labral tear
- Mild damage
- Significant bone damage
- Significant damage to the humeral head as well

## **Dr Doron Sher**

*M.B., B.S. (NSW), M.Biomed.E., F.R.A.C.S. (Ortho.)  
Knee, Elbow, Shoulder Surgery*



### **MY APPROACH:**

#### **1. No contact athlete with a labral tear:**

- 1) Arthroscopic stabilisation + posterior capsule plication +/- Remplissage
  - i. HAGL lesion – Open repair

#### **2. Contact Athlete with a labral tear**

- 1) Open stabilisation
  - i. If Posterior labral tear only – Arthroscopic Repair
  - ii. In season professional wanting to play again early but accepting a slightly higher re-injury rate – Arthroscopic stabilisation with posterior capsular plication and rotator interval closure– May need formal open repair later

#### **3. SLAP lesion – Arthroscopic Repair**

#### **4. Instability without labral tear**

- MDI / Non contact – Arthroscopic capsular plication
- Contact / Very Active Sports or Work / HAGL – Open Capsular Shift

#### **5. Mild Bone Damage**

- Non Contact – Arthroscopic repair with Remplissage
- Contact / Very Active Sports or Work / HAGL – Open Capsular Shift

#### **6. Significant Bone Damage**

- Laterjet Procedure

#### **7. Younger Patient**

- Usually male and often contact sports – Open Stabilisation

Recurrent shoulder instability is very common. These days we are operating earlier to try to prevent arthritis developing in the shoulder caused by multiple dislocations. It is important to assess the individual and their imaging before deciding which operation is appropriate for them.

Remember that there is more than one type of open surgery available to the patient. An open stabilisation has a very high success rate and far fewer potential complications than a Laterjet procedure. Arthroscopic surgery will still be used the majority of the time.



# ORTHOSPORTS



**NOTES:**

# ORTHOSPORTS



## THANK YOU FOR JOINING US TODAY

**Remember** - We would love your feedback

Tell us what you liked about the day and what you think we could improve for next year.

Please go directly to the link address or the QR code below to complete a **5 minute survey**

<https://www.surveymonkey.com/r/2022OrthoUpdates>



### CERTIFICATE OF ATTENDANCE

Should you wish to receive a **certificate of attendance** please complete the survey first.

You will then be given a unique code to email to [education@orthosports.com.au](mailto:education@orthosports.com.au)

Thank you,  
The Team at Orthosports

[www.orthosports.com.au](http://www.orthosports.com.au)



<b>Concord</b>	47-49 Burwood Road CONCORD NSW 2137	Tel Fax	<b>02 9744 2666</b> <b>02 9744 3706</b>	<b>Doctors Consulting here</b>	Dr Todd Gothelf Dr Samya Lakis Dr David Lieu Dr Paul Mason Dr John Negrine Dr Doron Sher Dr Christopher Spelman Dr Kwan Yeoh
<b>Hurstville</b>	Level 7 Waratah Private 29-31 Dora Street HURSTVILLE NSW 2220	Tel Fax	<b>02 9580 6066</b> <b>02 9580 0890</b>	<b>Doctors Consulting here</b>	Dr Paul Annett Dr Jerome Goldberg Dr Michael Goldberg Dr Todd Gothelf Dr Samya Lakis Dr Andreas Loeffler Dr John Negrine Dr Ivan Popoff Dr Kwan Yeoh
<b>Penrith</b>	Suite 5B 119-121 Lethbridge St PENRITH NSW 2750	Tel Fax	<b>02 4721 7799</b> <b>02 4721 7997</b>	<b>Doctors Consulting here</b>	Dr Todd Gothelf Dr Christopher Spelman Dr Kwan Yeoh
<b>Randwick</b>	160 Belmore Road RANDWICK NSW 2031	Tel Fax	<b>02 9399 5333</b> <b>02 9398 8673</b>	<b>Doctors Consulting here</b>	Dr John Best Dr Jerome Goldberg Dr Leigh Golding Dr Todd Gothelf Dr Samya Lakis Dr Andreas Loeffler Dr John Negrine Dr Ivan Popoff Dr Doron Sher Dr Christopher Spelman
<b>Bella Vista</b>	Suite 116, Level 1 Bldg B20, Lexington Drive BELLA VISTA NSW 2153	Tel Fax	<b>02 9744 2666</b> <b>02 9744 3706</b>	<b>Doctors Consulting here</b>	Dr Kwan Yeoh
<b>Canberra</b>	Lvl 2, 90 Corinna Street PHILLIP ACT 2606	Tel	<b>02 9580 6066</b>	<b>Doctors Consulting here</b>	Dr Samya Lakis Dr Christopher Spelman



47-49 Burwood Rd  
CONCORD NSW 2137  
Tel: 02 9744 2666  
Fax: 02 9744 3706

Lvl 7, 29-31 Dora Street  
HURSTVILLE NSW 2220  
Tel: 02 9580 6066  
Fax: 02 9580 0890

119-121 Lethbridge St  
PENRITH NSW 2750  
Tel: 02 4721 7799  
Fax: 02 4721 7997

160 Belmore Rd  
RANDWICK NSW 2031  
Tel: 02 9399 5333  
Fax: 02 9398 8673