



Welcome to our Autumn edition of Orthosports News

Dr George Konidaris brings us up to date on Unicompartmental Knee Replacement and Dr Doron Sher presents the Elbow Examination Series.

Dr Paul Annett kicks off the winter sport season with a timely article on the Over 35s soccer player.

We hope you enjoy this issue – The Team at Orthosports



AOA
AUSTRALIAN
ORTHOPAEDIC
ASSOCIATION

WHO ARE WE?

Orthosports is a professional association of Orthopaedic Surgeons based in Sydney.

ORTHOSPORTS LOCATIONS

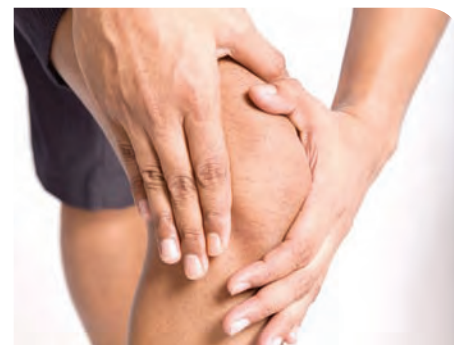> Concord 02 9744 2666
> Hurstville 02 9580 6066
> Penrith 02 4721 7799
> Randwick 02 9399 5333

Or visit our website

www.orthosports.com.au

Unicompartmental Knee Replacement (UKR) - 'Half Knee' Replacement

The aim of UKR is to alleviate the arthritic pain from the medial (usually) side of the knee. The patient tends to maintain their pre-operative ROM (if not improve it somewhat) compared to a total knee replacement where motion is almost always lost. Medial UKR is by far much more common than lateral UKR and the results of medial UKR are better.



UKR has been around for over 30 years. As prosthetic design and techniques of insertion improve its popularity and long term results are improving. Survivorship at 10 years has been excellent, ranging from 87.4% to 96%. Unfortunately for a few years they were inserted in inappropriate patients and the failure rate was unacceptably high on the Australian joint registry. If strict inclusion criteria are adhered to the results can be very good but this should be less than 10% of all knee replacements.

Traditionally inclusion criteria include:

- Noninflammatory arthritis
- < 10° of varus and < 5° of valgus
- Intact ACL/PCL
- > 90° of flexion

- No evidence of medio-lateral subluxation
- Flexion deformity < 15°
- Correctable deformity
- Stress radiographs demonstrating no collapse of the opposite compartment
- Patellofemoral cartilage changes grade 3 or lower and asymptomatic
- < 90 kg in weight, or < 30% over ideal body weight

Until recently UKRs have been reserved for older patients. More recently there have been some efforts to expand the indication for the procedure to include younger patients as well as patients with moderate involvement of the compartments not resurfaced (In younger patients it has been used as an alternative to an osteotomy). We are yet to see if this is a good idea or not.

There are theoretically some advantages of a UKR compared to osteotomy. These include a higher initial success rate, fewer early complications, more acceptable cosmetic appearance and perhaps a longer-lasting result. While it is

quite easy to convert a UKR to a Total Knee Replacement the results of this surgery are nowhere near as good as doing a primary knee replacement.

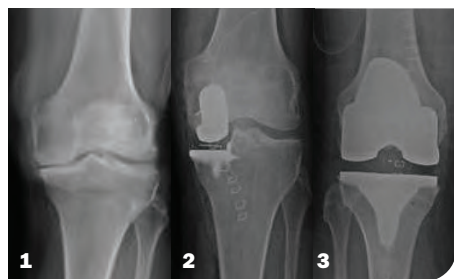
In the older population [octogenarians], the advantages of a UKR over a TKR include a smaller incision with less blood loss, less pain post operative, faster rehabilitation with better ROM and a more natural feel to the knee and less medical morbidity.

Unfortunately the results rapidly decline between 10-15 years after the surgery. This is usually related to progression of the arthritis, polyethylene wear and component loosening.

SUMMARY

UKR is a good operation for the older patient with isolated medial compartment OA in a stable knee with mild deformity. It has the potential for a quicker recovery and better function than a TKR but careful patient selection is required.

Dr George Konidaris



1. Normal knee, 2. Uni knee replacement, 3. Total knee replacement.

The over 35's Soccer Player

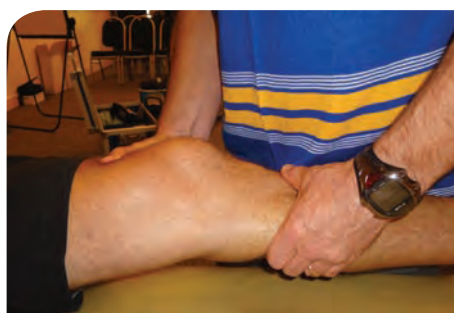This article has been prompted after many years of treating the 'over 35's' soccer players through my clinic. They are a significant injury demographic in their own right.

THE SCENARIO

David, aged 36, has a daughter who has just signed up to play with the local U6 soccer team. While David has a soccer background, his family has kept him off the pitch for a few years. He keeps fit going to the gym 2-3 times per week, but has put on 5-10kg. He hasn't performed 90 minutes of aerobic activity with repeat sprint efforts for some time.

It is suggested that the over 35's are looking for some more players and he thinks 'why not, I love playing soccer!'

This is the history I hear commonly from the patient sitting in my consultation room who has limped in with either an acute knee injury, or a hamstring or calf tear. Injury appears to be less common in players who have continued to play year in and out, than in those who have had a break, even for a year or two.



Lachman's test for acute ACL rupture.

RESOLVING THE PROBLEM

The first step is to improve general conditioning. The most common mistake made is to train once or twice and get straight in and play a game. Realistically the decision to play should be made early, at least 3 months before the season starts. A running based conditioning program should be undertaken for at least 6 weeks

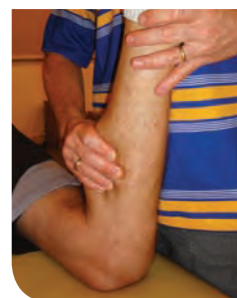prior to even starting football activity. This initially needs to include slower conditioning work, but should be upgraded to include both high intensity and direction change running. As a football code in particular soccer involves a combination of both continuous low intensity running and repeat sprint efforts. Most of us haven't trained with that degree of endurance or intensity since we were younger, and to try and reproduce it on aging hamstrings for 90 minutes is a recipe for injury.

Once the 6 week conditioning program is complete, then a period of 6 weeks of soccer specific practice, involving a continuation of speed and endurance conditioning, should be performed before playing games. This will hopefully provide a more 'soccer hardened' body, able to withstand traumatic muscle strains and injuries to the knee and ankle, as well as one more able to recover after games.

'PREHABILITATION' AND RECOVERY

The last component of a successful training program includes addressing 'prehabilitation' exercises and recovery techniques. The majority of players who are able to complete a conditioning program as described above would be ahead of the pack, but these last components are the 'extras' that may prevent injury. This would include a flexibility program, particularly for the glutes, hamstrings, quadriceps, hip flexors and calves. These should be performed on most days, and especially days after training and games. Exercise should involve strengthening for the thighs and buttocks (squats, lunges), core strength and proprioception or balance exercises. 'Core strength' is a fashionable term for the deep muscles supporting the spine and pelvis. It is excellent for treating patients with back problems, but also helpful in preventing hamstring tears and injury around the groin. Proprioceptive exercises involve using devices like a 'wobble board' to improve balance sense. This has been shown to reduce the incidence of injury to the knee and ankle.

Post game recovery techniques should also be considered. A post game warm down and stretch is recommended. Low intensity exercise the day after a game such as a walk, a swim or a light bike ride will aid muscle recovery and reduce delayed onset muscle soreness. A massage 1-2 days post game will also facilitate muscle recovery. Be careful not to neglect post game hydration, ideally not just with alcohol!



Thompson test for Achilles Tendon Rupture.

KEY POINTS

- Older athletes are more prone to injury, especially if participating in a new sport
- Common injuries in older athletes include hamstring and calf tears as well as knee and ankle ligament tears
- A pre-participation fitness program is an important factor in injury prevention
- This should include graded aerobic exercise, flexibility and core-strength
- Appropriate post activity management can improve recovery and reduce subsequent risk of injury.

Dr Paul Annett



ORTHOSPORTS
an RACGP
Accredited Activity Provider

MANAGEMENT OF ARTHRITIS
(Category 1 Module)

40 QI&CPD points with just 3 Hours of workshop time plus an online learning component.

We will be holding the workshop at our Concord, Randwick, Hurstville and Penrith rooms.

Email: education@orthosports.com.au for upcoming workshop dates.

KEY EXAMINATION POINTS



Elbow Examination

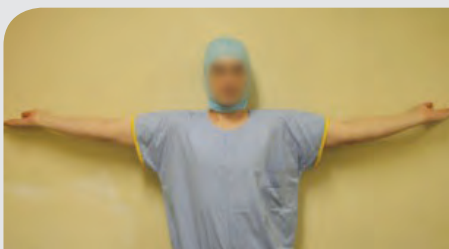Examination of the elbow can seem daunting because of the complexity of the joint. The history provides the diagnosis most of the time with the examination simply confirming what you already know.

Elbow complaints are broadly classified into acute or chronic injuries and the history and examination will differ greatly in these circumstances.

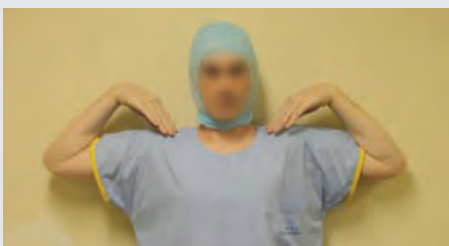The most common repetitive injuries are lateral and medial epicondylitis (tennis and golfers elbow) but strains of the triceps and biceps are possible too. PIN entrapment has a large overlap with lateral epicondylitis and radiocapitellar joint degeneration can present with pain in a similar area. Arthritis is less common in the elbow than in the weight bearing joints but is certainly a cause for locking, catching, loss of motion and pain.

Problems at the elbow can present with symptoms at the hand such as ulnar nerve compression causing numbness in the ulnar 2 fingers or pain radiating down the forearm.

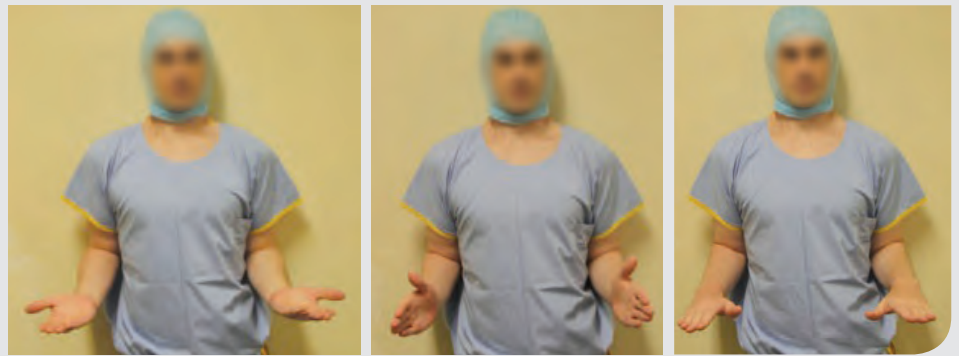
Acute injuries include fractures, dislocations or tendon avulsions. The most common of these are radial head fractures and distal biceps tears.



Elbow extension.



Elbow flexion.



From left: forearm supination, forearms in neutral, and forearm pronation.

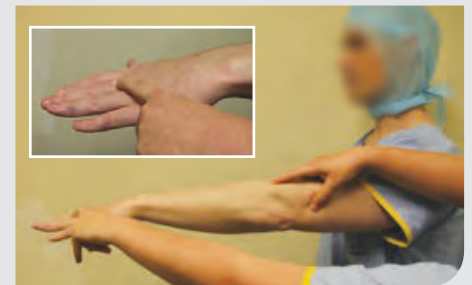Less commonly the elbow is over stretched in a particular direction or actually dislocated from a fall on an outstretched hand. The mechanism of injury in these situations is very helpful when trying to decide on treatment and a detailed history of the injury should always be taken.

Sometimes there will be minimal or no trauma such as olecranon bursitis. This is usually a painless swelling with no infection which is a nuisance only. When infected it may require treatment with antibiotics and splinting and occasionally an operative washout.

Always ask which is the patient's dominant hand, what work they do and what sports they play. Repetitive work or recreation activities can lead to overuse injuries at the elbow. Problems in the neck can also present with arm pain which can be mistakenly attributed to the elbow.

- A) Ask the patient to stand with their arms by their sides. Look at the arms and elbow from the front and the back.
- B) Ask the patient to fully straighten and then fully bend the elbows. Check pronation and supination to assess the proximal and distal radio-ulnar joints and always compare this to the unaffected side.
- C) Look for joint swelling
- D) Palpate all prominences
 - 1) Medial epicondyle
 - 2) Ulnar nerve
 - 3) Olecranon
 - 4) Lateral epicondyle
 - 5) Radial head

- E) Feel the various muscles and tendons for tenderness or tears
 - 1) Triceps
 - 2) Biceps
 - 3) Wrist flexors
 - 4) Wrist extensors: "the mobile wad of three"
- F) Check muscle power in the hand and elbow and compare it to the unaffected side.
- G) The resisted extension test is very accurate for diagnosing lateral epicondylitis. Ask the patient to straighten their elbow, wrist and fingers and press down on the long finger while they try to keep it straight. Pain at the lateral epicondyle confirms the diagnosis of tennis elbow.



The Resisted extension test.

INVESTIGATIONS

Always start with plain Xrays of the elbow. An AP, Lateral and Oblique are the 3 minimum views. If these are normal and you suspect a loose body or fracture then a CT scan should be the next test ordered. It is rare for me to order other tests. Muscle tears are usually obvious clinically but can be confirmed on MRI scanning. Ultrasound has limited usefulness but can be used to localise a nerve or look for a cyst. Bone scan can show fractures, arthritis or CRPS as well as epicondylitis.

Dr Doron Sher

Orthopaedic Surgeons and their Interests

LOCATION	SURGEON	SPECIALTY
CONCORD 47-49 Burwood Road Concord NSW 2137 Tel: 02 9744 2666	Dr Todd Gothelf	Foot & Ankle, Shoulder
	Dr George Konidaris	Foot & Ankle, Hip and Knee
	Dr John Negrine	Foot & Ankle (Adult)
	Dr Rodney Pattinson	Paediatrics and General Orthopaedics
	Dr Doron Sher	Knee, Shoulder and Elbow
	Dr Kwan Yeoh	Hand, Upper Limb and General Orthopaedics
HURSTVILLE Medica Centre 29-31 Dora Street Hurstville NSW 2220 Tel: 02 9580 6066	Dr Jerome Goldberg	Shoulder
	Dr Todd Gothelf	Foot & Ankle, Shoulder
	Dr George Konidaris	Foot & Ankle, Hip and Knee
	Dr Andreas Loeffler	Spine, Trauma, Hip and Knee
	Dr John Negrine	Foot & Ankle (Adult)
	Dr Rodney Pattinson	Paediatrics and General Orthopaedics
	Dr Ivan Popoff	Shoulder, Knee and Elbow
	Dr Allen Turnbull	Hip and Knee
	Dr Kwan Yeoh	Hand, Upper Limb and General Orthopaedics
PENRITH Suite 5B, 119-121 Letherbridge Street, Penrith NSW 2750 Tel: 02 4721 7799	Dr Todd Gothelf	Foot & Ankle, Shoulder
	Dr George Konidaris	Foot & Ankle, Hip and Knee
	Dr Kwan Yeoh	Hand, Upper Limb and General Orthopaedics
RANDWICK 160 Belmore Road Randwick NSW 2031 Tel: 02 9399 5333	Dr Jerome Goldberg	Shoulder
	Dr Todd Gothelf	Foot & Ankle, Shoulder
	Dr George Konidaris	Foot & Ankle, Hip and Knee
	Dr Andreas Loeffler	Spine, Trauma, Hip and Knee
	Dr John Negrine	Foot & Ankle (Adult)
	Dr Rodney Pattinson	Paediatrics and General Orthopaedics
	Dr Ivan Popoff	Shoulder, Knee and Elbow
	Dr Doron Sher	Knee, Shoulder and Elbow
	Dr Kwan Yeoh	Hand, Upper Limb and General Orthopaedics

Sport & Exercise Medicine Physicians

PHYSICIAN	LOCATION	PHYSICIAN	LOCATION
Dr Paul Annett	Hurstville	Dr Mel Cusi	Concord Hurstville Randwick
Dr John Best	Randwick		



M.B.B.S (NSW)
F.R.A.C.S (Ortho)
Orthopaedic Surgeon

Spotlight on Dr George Konidaris

Dr Konidaris graduated from the University of NSW in 1997. Prior to undertaking his Orthopaedic surgical training Dr Konidaris worked as a doctor at the NSW Institute of Sports Medicine. He treated both professional and amateur athletes with acute and chronic sports related injuries.

Over the past decade Dr Konidaris has trained and worked in Sydney, Newcastle and

Adelaide and has worked in major trauma centres in Sydney and Newcastle.

Dr Konidaris has an interest in orthopaedic conditions of the lower limb (hip, knee, foot and ankle) as well as general orthopaedics and orthopaedic trauma.

Dr Konidaris consults from our Concord, Hurstville, Penrith and Randwick offices.

As a friend of Orthosports you have been included on our mailing list to receive this newsletter. Should you wish to unsubscribe please email education@orthosports.com.au or contact one of our offices directly.

www.orthosports.com.au