



**Our final edition for 2014** includes an article from Dr Kwan Yeoh on Carpal Tunnel Syndrome in pregnancy.

Dr Doron Sher looks at graft choice in ACL reconstruction and covers MRI of the Knee on page 3.

Our RACGP Accredited modules continue to be popular with the GP community. To date over 450 GPs have completed one or both of our Category 1 Modules. We will be running further Category 1 modules in 2015.

*We wish you all the best for the festive season*  
The Team at Orthosports



## WHO ARE WE?

Orthosports is a professional association of Orthopaedic Surgeons based in Sydney.

## ORTHOSPORTS LOCATIONS

- > Concord 02 9744 2666
- > Hurstville 02 9580 6066
- > Penrith 02 4721 7799
- > Randwick 02 9399 5333

Or visit our website  
[www.orthosports.com.au](http://www.orthosports.com.au)

## Carpal tunnel syndrome in pregnancy

**Carpal tunnel syndrome (CTS)** is very common, affecting up to 62% of pregnancies. The **presenting symptoms** are similar to those in non-pregnant patients: paraesthesia, pain, numbness, weakness, clumsiness, provocation by repetitive movements and sleep, and mitigation with changes in posture and by shaking the hand. CTS is primarily a clinical diagnosis, as electrophysiological tests may be normal even in the presence of disease.

**I**t is not known why CTS occurs more during pregnancy. Fluid retention may lead to oedema within the carpal tunnel tissues, perhaps causing a mechanical compression of the median nerve. Perhaps impaired glucose tolerance during pregnancy predisposes to CTS. A generalised nerve hypersensitivity has also been shown in pregnant women, perhaps contributing to CTS.

It is commonly believed that CTS resolves in the post-partum period. However, symptoms often do not

resolve until after breastfeeding has ceased. Some studies have shown that residual symptoms were still present in over half the affected women long after delivery, often worsening sufficiently to warrant carpal tunnel release between 2 and 16 years after delivery.

**Non-surgical treatment** is almost always the first step. Wrist splints including a solid volar support with the wrist in a neutral position should be worn at night. Steroid injections may be given "blind" or under ultrasound guidance into the carpal tunnel. Both splints and injections have been found to have equal efficacy of about 85-90%.

If non-surgical treatment fails, then carpal tunnel release can be considered. Surgery may also be considered in very severe disease, as surgery gives a more predictable outcome more quickly than non-surgical management.

Of course, one has to consider the risk of surgery. There is minimal risk to mother or child when *carpal tunnel release* is performed under local anaesthesia and tourniquet control. A study of surgical release under local anaesthesia for pregnancy-related CTS reported a 96% good-excellent result in those operated on during the third trimester, with an overall good-excellent result of 98% for all patients in the study.

In *summary*, carpal tunnel syndrome is very common during pregnancy and may not resolve as fully as is commonly believed. Non-surgical treatment with splints and steroid injections is effective in 85-90% of patients, but carpal tunnel release performed under local anaesthesia is a safe and effective treatment.

*Dr Kwan Yeoh*



# Graft Choice for ACL Reconstruction

*One of the surgeon's roles in ACL reconstructive surgery is to individualize the graft choice for each patient. The patient's occupation, the type of sport they play, their skeletal age, associated ligamentous pathology, the chronicity of the injury, and their inherent degree of ligamentous laxity are important factors to consider.*

**R**egardless of the graft chosen it probably takes 9 months for the neurological function of the knee to return to normal to reduce the likelihood of re-injury with return to sport.

Many materials have been used over the years. Some have worked well but others have failed rapidly. The main graft choices today are: Middle one third of patellar tendon with bone blocks, quadrupled hamstring tendons, synthetics, quadriceps with or without bone block and allografts.

## PATELLAR TENDON

The major advantage of the patella tendon is that you get early bone to bone healing at 6 weeks. Patients with excessive joint laxity are probably better off with this graft (rather than hamstring autograft) at 2-year follow-up.

The disadvantages of this technique relate mainly to problems at the front of the knee such as anterior knee pain and problems kneeling.

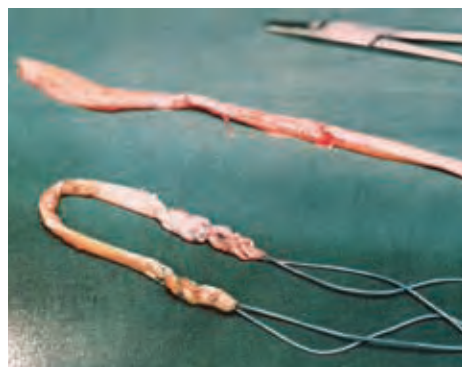## HAMSTRING AUTOGRAFT

The advantage of using the patient's hamstrings is that they tend to have less anterior knee pain and less pain on kneeling. While the graft is initially quite stiff and strong it can stretch out over time.

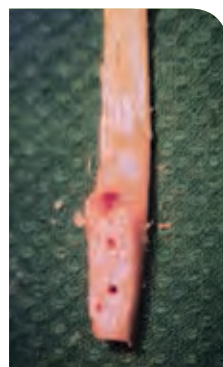
One of the disadvantages of this technique is that harvesting the tendon can be more difficult than harvesting a patella tendon graft. It also takes longer to achieve graft healing to bone (approximately 10-12 weeks). There is a slightly increased objective laxity in knees with hamstring tendons compared to patella tendon grafts but the clinical significance of a mean difference of 0.8mm is unclear.

## SYNTHETICS

The initial attraction of synthetics was as an alternative to the patellar tendon graft harvest problems. However, with long term follow up the failures became unacceptable. LAD (ligament augmentation device), Leeds Keio, Gore-Tex, Dacron – all failed but often not until about 7 years post surgery. There is a real concern the same thing will happen with the LARS ligament which is currently quite fashionable.



Hamstring tendon graft



Patella tendon graft with bone block

## ALLOGRAFT

Allografts were initially sterilized using ethylene oxide which led to very poor results because the graft was weak and failed easily. Freeze dried, fresh frozen and cryopreserved seem to perform better. The major advantages of using an allograft are the avoidance of harvest site morbidity and having a shorter operative time.

The disadvantages are the risk of disease transmission (HIV transmission with connective tissue allografts is estimated to be 1 : 600,000 and for bacterial infections 26 : 1,000,000). The graft can be weak if it is irradiated or from an older patient, is expensive and has a higher failure rate in young, active patients.

## QUADRICEPS TENDON

The quadriceps tendon is becoming a more common graft source because it is easy to harvest, has a large cross sectional size and can be taken without a bone block.

## CONCLUSION

Errors in graft selection, tunnel placement, tensioning, or fixation methods lead to graft failure. The most important aspect of the operation is to place the tunnels in the correct position. The choice of graft is really incidental. If nonanatomic techniques are used; it makes no difference which type of graft is used, the risk of graft failure is highly increased.

The majority of patients are suitable for a hamstring tendon autograft reconstruction. My personal view is that synthetic grafts are too risky to use in young active patients and that allografts should be reserved for older patients. Patella tendon grafts also work very well and while the patients may find recovery somewhat slower it does give them a 'tighter' knee in the long run.

Dr Doron Sher



Sydney  
Shoulder  
Clinic

A sub-group of Orthosports, The Sydney Shoulder Clinic is a specialist shoulder service providing clinical care in physiotherapy, sport & exercise medicine and orthopaedic surgery.  
[www.sydneyshoulderclinic.com.au](http://www.sydneyshoulderclinic.com.au)

## KEY EXAMINATION POINTS



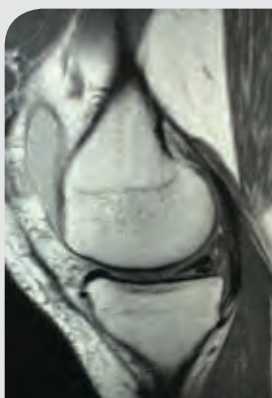
### Magnetic Resonance Imaging of the Knee

MRI scanning is an imaging modality that provides detailed images of the soft tissues of the knee.

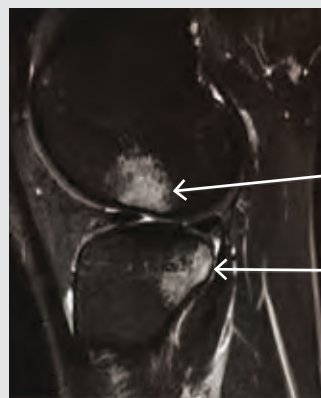#### TECHNICAL ASPECTS

MRI uses powerful magnets to affect water containing tissues in the body. The magnetic field forces the hydrogen ions to all 'line up' and point the same direction. This force is then removed which allows the hydrogen ions to go back to a more 'stable' state (precessing). As they do so they release energy which is detected by sensors and turned into images. The magnetic field can be applied in different ways and for different periods of time to maximize visualization of different tissues such as fat, muscle or bone. The two most common sequences are T1 and T2 sequences with T1 showing 'anatomy' and T2 showing 'pathology'. The contrast between different tissues is determined by the rate at which excited atoms return to their **equilibrium state**.

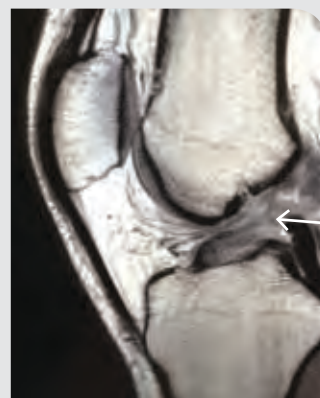
The MRI scanner forms a strong and uniform **magnetic** field around the area to be imaged. The field strength of the magnet is measured in tesla and, generally speaking, the higher



*Tear of the medial meniscus seen on a Sagittal T1 weighted image*



*Typical Bone Bruising seen on the Femur and Tibia after an ACL tear seen on a Sagittal T2 weighted image*



*Arrow indicates the torn ACL seen on a Sagittal T1 weighted image.*

the **tesla** number the more detailed the images are that are produced. At least 3 imaging planes are acquired: Sagittal, Axial and Coronal.

*The findings on MRI depend on the quality of the study, and are influenced by technical factors such as magnet strength, imaging planes, and use of surface coils as well as the experience of the radiologist reporting them.*

#### WHEN TO ORDER A MRI

A careful physical examination combined with plain xrays can often provide the diagnosis without a MRI scan (and at a substantially lower cost). Matching the pathology seen on the scan to the patients complaint is also important, as MRI has been shown to reveal cartilage lesions, osteophytes, and meniscal abnormalities in **asymptomatic** study volunteers with no history of pain, trauma or knee disease.

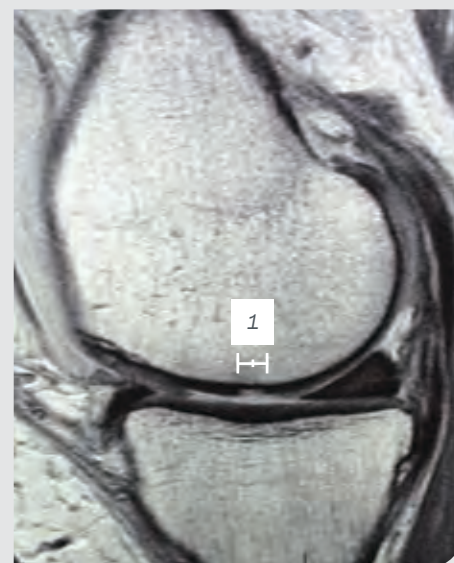
When there has been some internal derangement of the knee, the MRI is very useful to confirm the clinical diagnosis. This includes ACL or PCL injury, meniscal tears and patella instability. A Baker's cyst and tendonitis are also well seen.

#### HOW TO READ THE SCAN

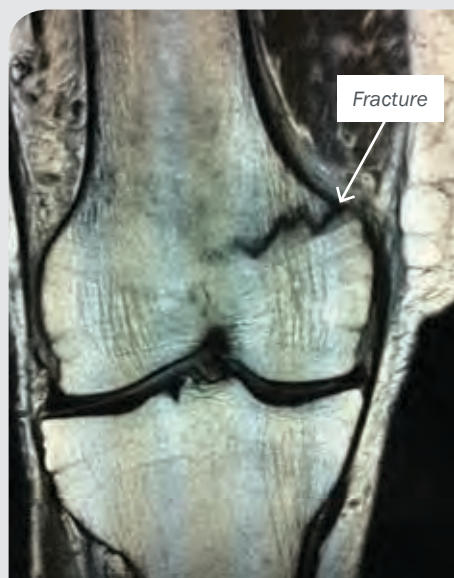While all 3 planes are used to make a diagnosis the sagittal images are particularly good for looking at ACL and patella tendon. Axial images show the patellofemoral joint, Cruciates and popliteal fossa. The coronal images show menisci, ligaments and articular

cartilage. In order to diagnose a meniscal tear the tear must be seen to extend to the meniscal surface on 2 sequential images.

Included below are examples of common pathology seen on MRI scans. The RACGP has produced a very helpful document with clinical guidance for MRI referral: <http://www.racgp.org.au/your-practice/guidelines/mri-referral/mri-of-the-knee/>



*Chondral injury of the femoral condyle seen on a Sagittal T1 weighted image*



*Fracture of the medial femoral condyle seen on coronal T1 weighted image*

Ordering an MRI does not replace a careful clinical examination of the patient and is not always the most appropriate imaging modality to use. Treatment should be targeted towards the patient's symptoms rather than at all the abnormalities seen on the MRI. When combined with a careful clinical examination it is a very powerful diagnostic tool.

*Dr Doron Sher*

## Orthopaedic Surgeons and their Interests

### CONCORD

47-49 Burwood Road Concord NSW 2137  
Tel: 02 9744 2666

Dr Todd Gothelf	Foot & Ankle, Shoulder
Dr George Konidaris	Foot & Ankle, Hip and Knee
Dr John Negrine	Foot & Ankle (Adult)
Dr Rodney Pattinson	Paediatrics and General Orthopaedics
Dr Doron Sher	Knee, Shoulder and Elbow
Dr Kwan Yeoh	Hand, Upper Limb and General Orthopaedics

### HURSTVILLE

Medica Centre 29-31 Dora Street Hurstville NSW 2220  
Tel: 02 9580 6066

Dr Jerome Goldberg	Shoulder
Dr Todd Gothelf	Foot & Ankle, Shoulder
Dr Andreas Loeffler	Spine, Trauma, Hip and Knee
Dr John Negrine	Foot & Ankle (Adult)
Dr Rodney Pattinson	Paediatrics and General Orthopaedics
Dr Ivan Popoff	Shoulder, Knee and Elbow
Dr Allen Turnbull	Hip and Knee
Dr Kwan Yeoh	Hand, Upper Limb and General Orthopaedics

### PENRITH

Suite 5B, 119-121 Lethbridge Street, Penrith NSW 2750  
Tel: 02 4721 7799

Dr Todd Gothelf	Foot & Ankle, Shoulder
Dr Kwan Yeoh	Hand, Upper Limb and General Orthopaedics

### RANDWICK

160 Belmore Road Randwick NSW 2031  
Tel: 02 9399 5333

Dr Jerome Goldberg	Shoulder
Dr Todd Gothelf	Foot & Ankle, Shoulder
Dr George Konidaris	Foot & Ankle, Hip and Knee
Dr Andreas Loeffler	Spine, Trauma, Hip and Knee
Dr John Negrine	Foot & Ankle (Adult)
Dr Rodney Pattinson	Paediatrics and General Orthopaedics
Dr Ivan Popoff	Shoulder, Knee and Elbow
Dr Doron Sher	Knee, Shoulder and Elbow

### Sport & Exercise Medicine Physicians

Dr Paul Annett	Hurstville
Dr John Best	Randwick
Dr Mel Cusi	Concord   Hurstville   Randwick

## ORTHOSPORTS – RACGP ACCREDITED ACTIVITY PROVIDER:

Our Category 1 modules are designed to offer flexibility and educational hands on learning.

- 3 hours of convenient online learning and
- 3 hours of workshop time (6.30pm-9.30pm)

### CATEGORY 1 MODULES (40 CPD POINTS) – 2015 WORKSHOPS

Shoulder Pain & Injury Management 40 Category 1 CPD points

Management of Knee Arthritis 40 Category 1 CPD points



Dates for 2015 will be confirmed soon  
– to register your interest or for more  
information please email  
[education@orthosports.com.au](mailto:education@orthosports.com.au)

#### SOME COMMENTS RECEIVED FROM GPS:

“An excellent meeting. It was among the best I have ever attended.”  
“I was very impressed by both the online and face to face components  
and found it very useful in updating my knowledge.”

Should you wish to unsubscribe please email [education@orthosports.com.au](mailto:education@orthosports.com.au) or contact one of our offices directly.

[www.orthosports.com.au](http://www.orthosports.com.au)

ARTHROSCOPY | JOINT REPLACEMENT | LIGAMENT RECONSTRUCTION | PHYSIOTHERAPY | SPORT & EXERCISE MEDICINE