

FIFTH METATARSAL FRACTURES

ORTHOSPORTS



Todd Gothelf

MD (USA), FRACS, FAAOS, Dip. ABOS

Foot, Ankle, Shoulder Surgeon

You have been diagnosed with a fracture of the fifth metatarsal bone. This type of fracture usually occurs when the ankle suddenly rolls inward. When the ankle rolls, a tendon that is attached to the fifth metatarsal bone is stretched. Because the bone is weaker than the tendon, the bone cracks first.

All bones heal in a different way when they break. This is especially true of the fifth metatarsal bone. In addition, the blood supply varies to different areas, making it a lot harder for some fractures to heal without help. Below are descriptions of the main patterns of fractures of the fifth metatarsal fractures and treatments for each.

FIFTH METATARSAL AVULSION FRACTURE

This fracture pattern occurs at the tip of the bone (figure 1). These fractures have a very high rate of healing and require little protection. Weight on the foot is allowed as soon as the patient is comfortable. While crutches may help initially, walking without them is allowed. I prefer to place patients in a walking boot, as it allows for more comfortable walking and protects the foot from further injury. RICE treatment is initiated. Pain should be expected to diminish over the first four weeks, but may not completely go away for several months.

Follow-up radiographs are not necessary if the pain resolves as expected. The walking boot can be discontinued at 4-6 weeks and regular walking started. Return to running and sports should be delayed for six weeks. Physiotherapy is initiated and a brace worn to avoid re-injury.

Orthopaedic Surgeons

J. Goldberg
A. Turnbull
R. Pattinson
A. Loeffler
J. Negrine
I. Popoff
D. Sher
T. Gothelf

Sports Physicians

J. Best
M. Cusi
P. Annett

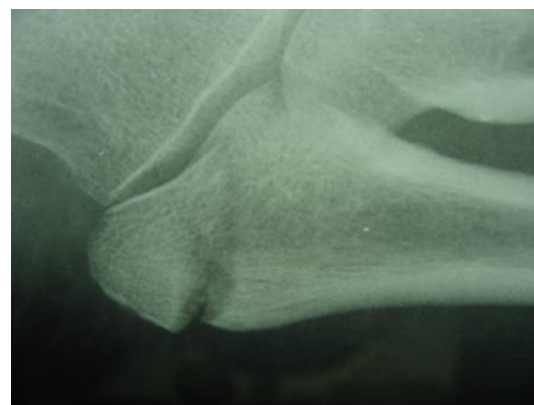


Figure 1: Avulsion Fracture

JONE'S FRACTURE

At a very specific location on the fifth metatarsal, the blood supply to the bone is poor (figure 2). Sir Francis Jones described this fracture as special due to its lack of blood supply and relatively high risk that the bone does not heal.

Jone's fractures can be treated in a cast, non-weightbearing for six weeks, or with surgery. Surgery is considered if this treatment plan cannot be followed. I will usually plan to see the patient at six weeks after the fracture. X-rays should be done JUST BEFORE the doctor visit so the doctor can review the x-rays and assess the foot for healing. Usually at the six week mark the patient can start walking without the boot, and physiotherapy can be initiated.

If the fracture looks like it is not healing, then surgery is considered. Surgery involves a small incision and placement of a screw in the bone across the fracture to compress the edges and promote healing. Sometimes bone graft is taken from the calcaneus bone if the fracture is chronic. The success rate of the surgery is 80%.

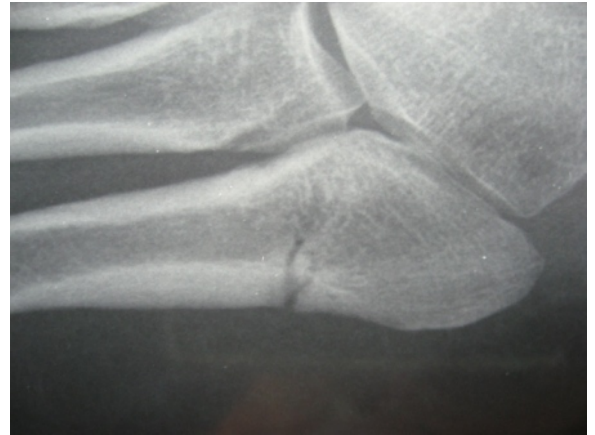


Figure 2: Jones Fracture

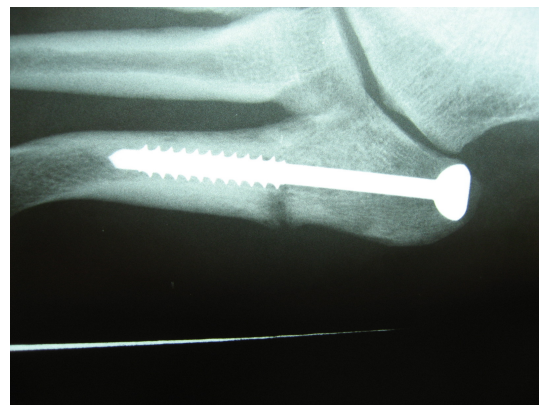

Figure 3: Fixation with Screw

DISTAL SHAFT FRACTURE

This fracture commonly occurs when the fifth toe gets caught on an object after a trip or a fall (figure 5). Although the x-rays can reveal fragments have separated, these fractures usually do not deform the 5th toe, and are not noticeable from the outside. Non-operative treatment in a boot or a cast is the standard treatment. Walking on the foot can begin after two weeks.

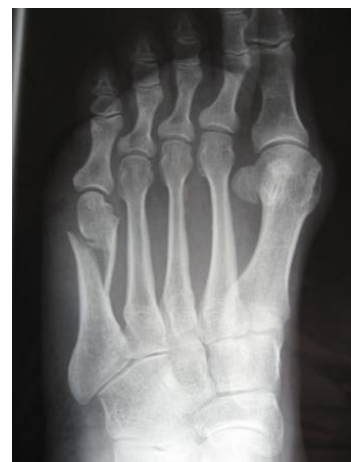

Figure 4: Distal shaft fracture