

Dr Ivan Popoff

www.orthosports.com.au

29-31 Dora Street, Hurstville
160 Belmore Road, Randwick



ORTHOSPORTS

ORTHOPAEDIC & SPORTS MEDICINE SERVICE

Dr Ivan Popoff
Knee, Elbow & Shoulder Surgery

Case 1



ORTHOSPORTS

ORTHOPAEDIC & SPORTS MEDICINE SERVICE

Dr Ivan Popoff
Knee, Elbow & Shoulder Surgery

History

- 20 year old elite Rugby player
- no history of dislocation
- Forced Abduction External Rotation injury in while tackling
- Sever pain, loss of function, deformity
- Dx anterior dislocation
- Reduced by team physio



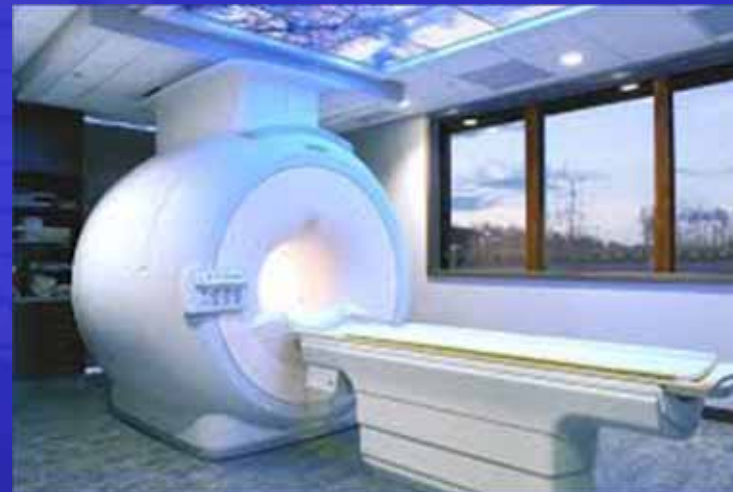ORTHOSPORTS

ORTHOPAEDIC & SPORTS MEDICINE SERVICE

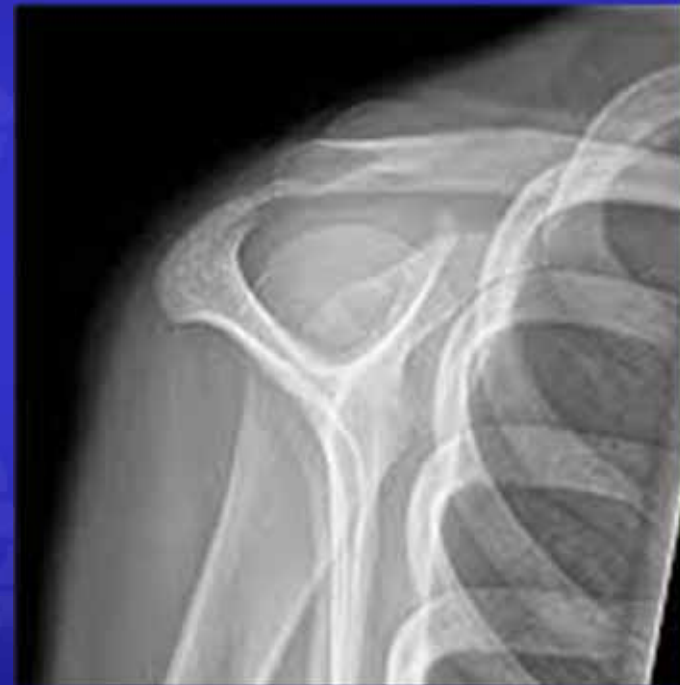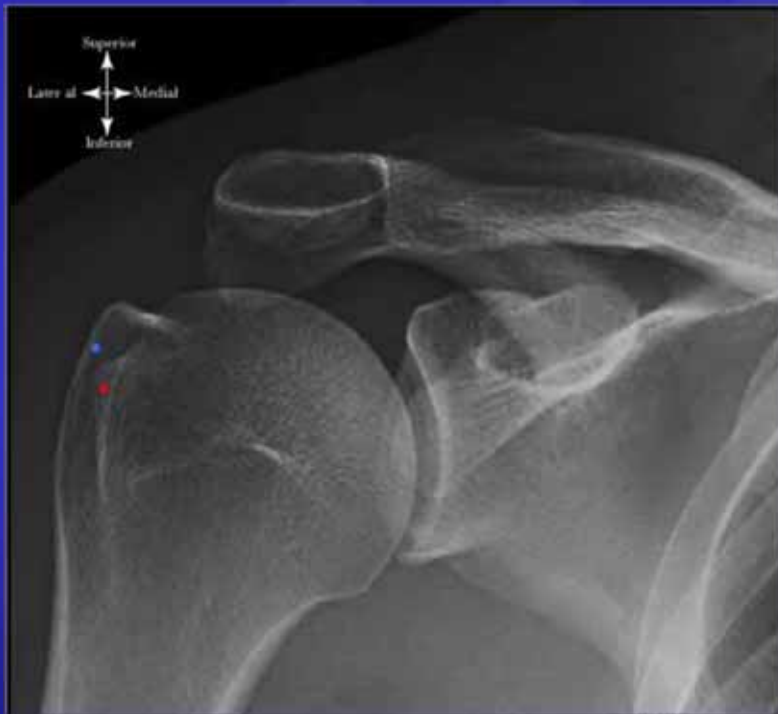Dr Ivan Popoff
Knee, Elbow & Shoulder Surgery

What is the most appropriate initial investigation

- A. Ultrasound
- B. X-ray
- C. MRI
- D. CT scan
- E. Bone Scan



X-Ray



ORTHOSPORTS
ORTHOPAEDIC & SPORTS MEDICINE SERVICE

Dr Ivan Popoff
Knee, Elbow & Shoulder Surgery

Examination

- N/V intact
- Poor elevation
- External rotation strength 4/5
- Napoleons test positive



ORTHOSPORTS

ORTHOPAEDIC & SPORTS MEDICINE SERVICE

Dr Ivan Popoff
Knee, Elbow & Shoulder Surgery

Initial Treatment

- A. Sling immobilisation for 6 weeks
- B. Abduction brace in neutral rotation for 6 weeks
- C. Urgent surgery
- D. Sling for comfort, then physiotherapy
- E. Body binder for 6 weeks

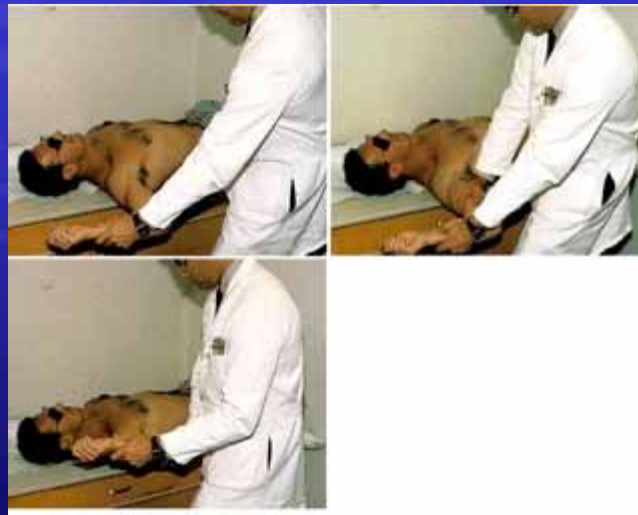

6 week Examination

Full ROM mild painful arc

Rotator Cuff strength 5/5

Positive apprehension and relocation tests



ORTHOSPORTS

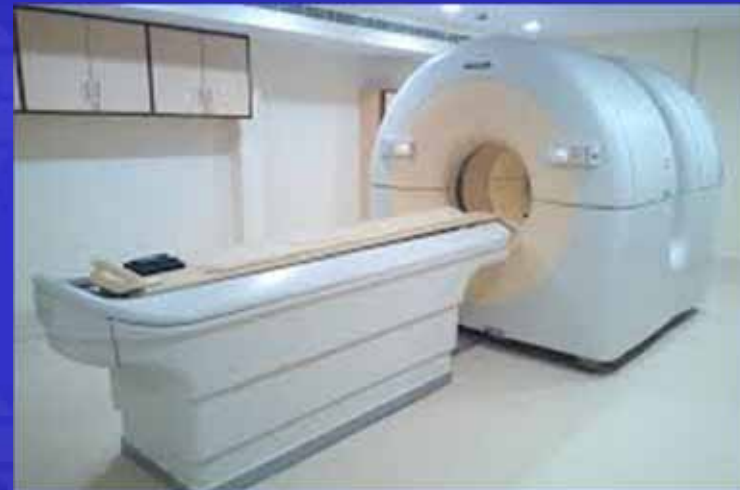ORTHOPAEDIC & SPORTS MEDICINE SERVICE

Dr Ivan Popoff

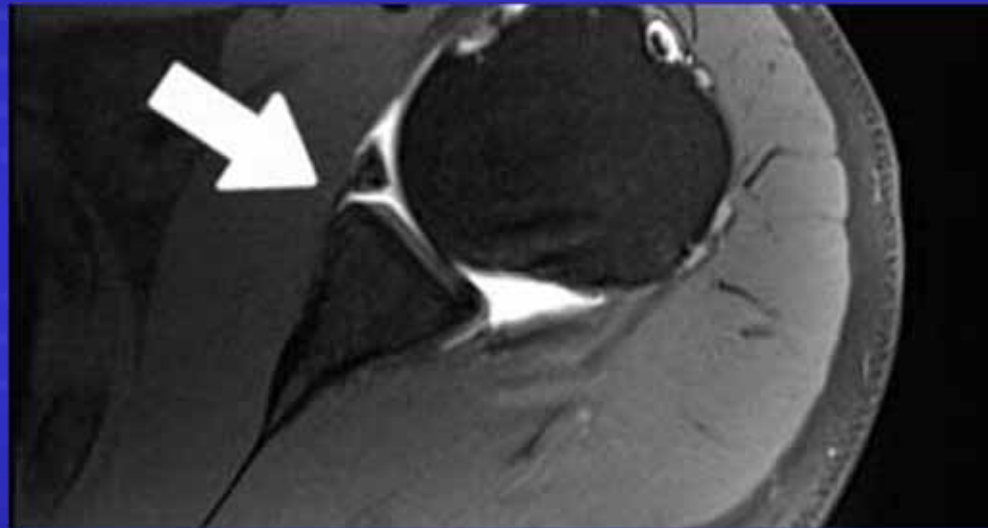
Knee, Elbow & Shoulder Surgery

Investigations

- A. CT
- B. Ultra- sound
- C. MRI
- D. MRI arthrogram
- E. PET scan



MRI Arthrogram

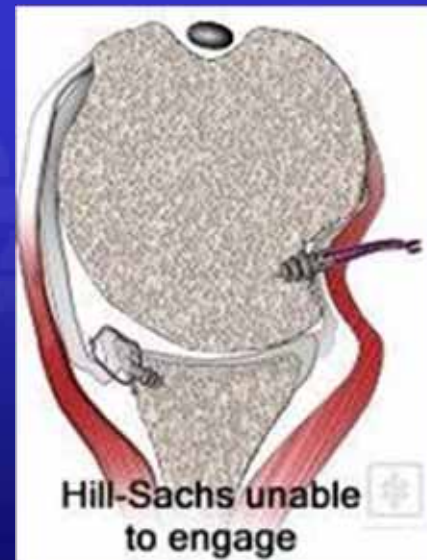

ORTHOSPORTS
ORTHOPAEDIC & SPORTS MEDICINE SERVICE

Dr Ivan Popoff
Knee, Elbow & Shoulder Surgery

Treatment

- A. Continue Physio
- B. Arthroscopic Stabilisation
- C. Arthroscopic Stabilisation and Remplissage
- D. Open Stabilisation
- E. Latarjet Procedure



Dr Ivan Popoff

Knee, Elbow & Shoulder Surgery



ORTHOSPORTS

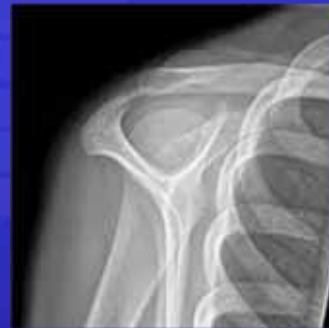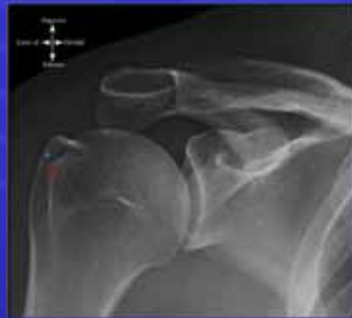ORTHOPAEDIC & SPORTS MEDICINE SERVICE

Case 2

75 year old woman fall at home

A & E - Dx dislocated shoulder reduced

X rays



Sling Reassured LMO



ORTHOSPORTS

ORTHOPAEDIC & SPORTS MEDICINE SERVICE

Dr Ivan Popoff
Knee, Elbow & Shoulder Surgery

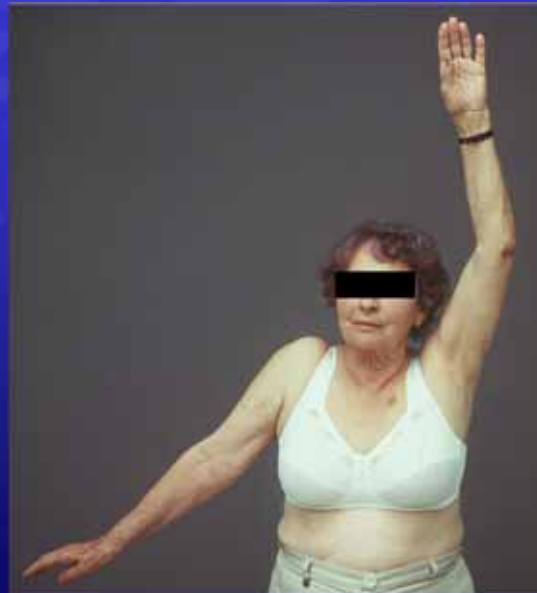Examination

Poor active elevation

Passive ROM intact -painful

External rotation strength 3/5

N/V intact



Diagnosis

- A. Frozen Shoulder
- B. Osteoarthritis
- C. Locked Dislocation
- D. Stroke
- E. Massive Rotator Cuff tear



ORTHOSPORTS

ORTHOPAEDIC & SPORTS MEDICINE SERVICE

Dr Ivan Popoff
Knee, Elbow & Shoulder Surgery

Investigations

- A. Ultrasound
- B. CT scan
- C. MRI arthrogram shoulder
- D. MRI brain
- E. X ray axillary view

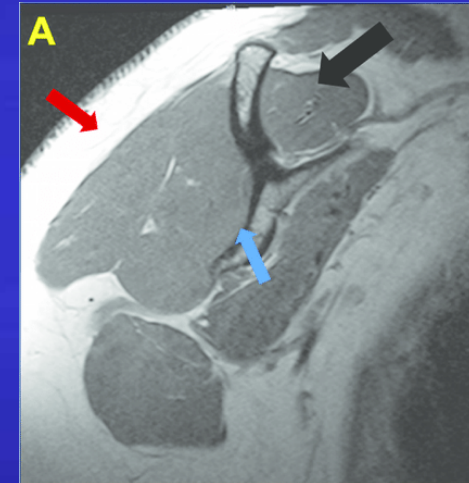
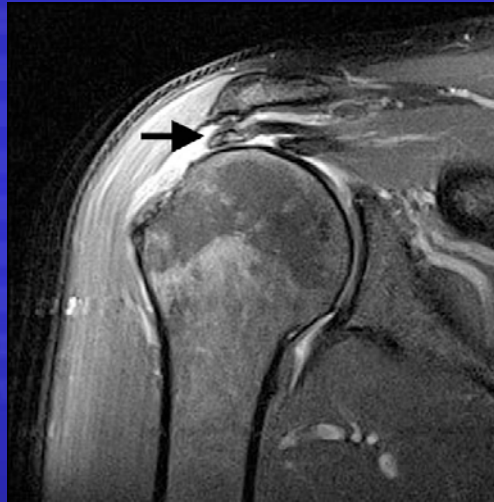
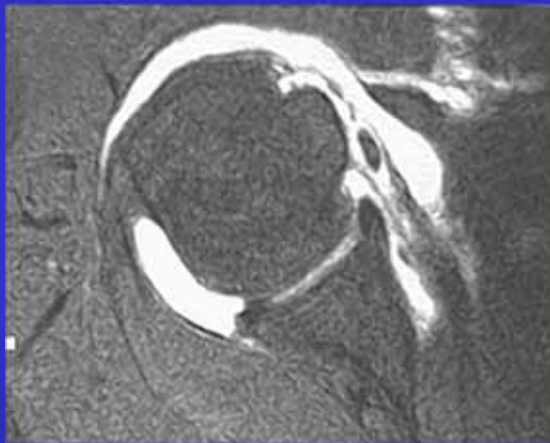


ORTHOSPORTS

ORTHOPAEDIC & SPORTS MEDICINE SERVICE

Dr Ivan Popoff
Knee, Elbow & Shoulder Surgery

MRI arthrogram



Treatment

- A. Physiotherapy
- B. Corticosteroid injection and Physiotherapy
- C. Open Rotator Cuff Repair
- D. Arthroscopic Rotator Cuff Repair
- E. Reverse Total Shoulder Replacement



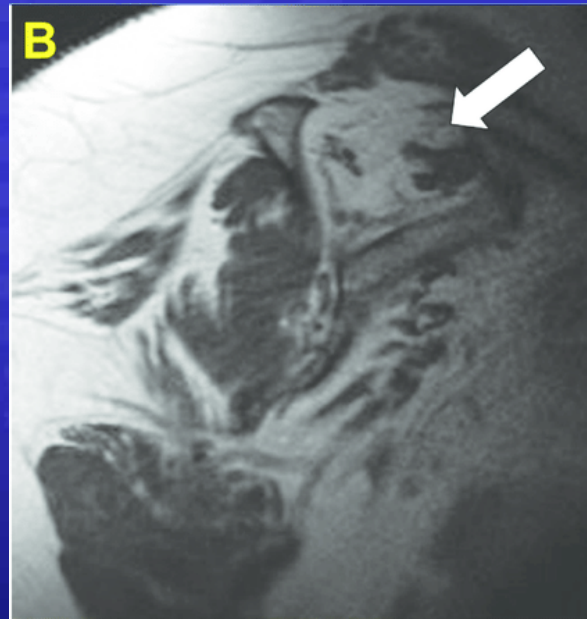
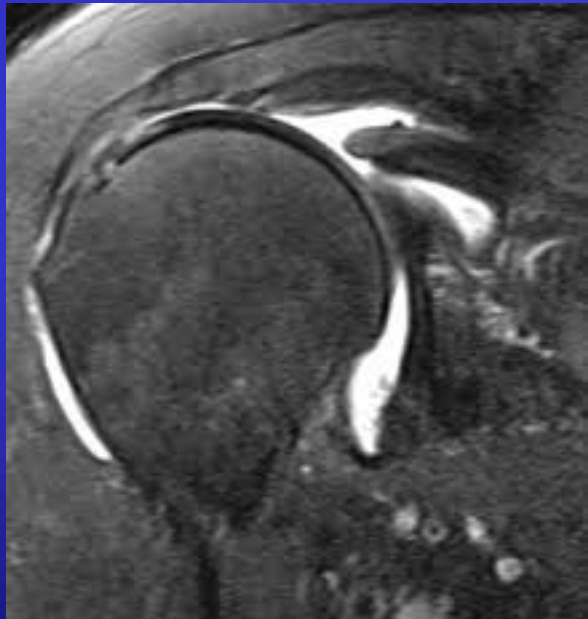
ORTHOSPORTS

ORTHOPAEDIC & SPORTS MEDICINE SERVICE

Dr Ivan Popoff
Knee, Elbow & Shoulder Surgery

Case 3

Same as Case 2 but injury 8 months old



ORTHOSPORTS

ORTHOPAEDIC & SPORTS MEDICINE SERVICE

Dr Ivan Popoff
Knee, Elbow & Shoulder Surgery

Treatment

- A. Physiotherapy
- B. Corticosteroid injection and Physiotherapy
- C. Open Rotator Cuff Repair
- D. Arthroscopic Rotator Cuff Repair
- E. Reverse Total Shoulder Replacement



ORTHOSPORTS

ORTHOPAEDIC & SPORTS MEDICINE SERVICE

Dr Ivan Popoff
Knee, Elbow & Shoulder Surgery