

Dr Paul Annett

“Sciatica”

www.orthosports.com.au

29-31 Dora Street, Hurstville



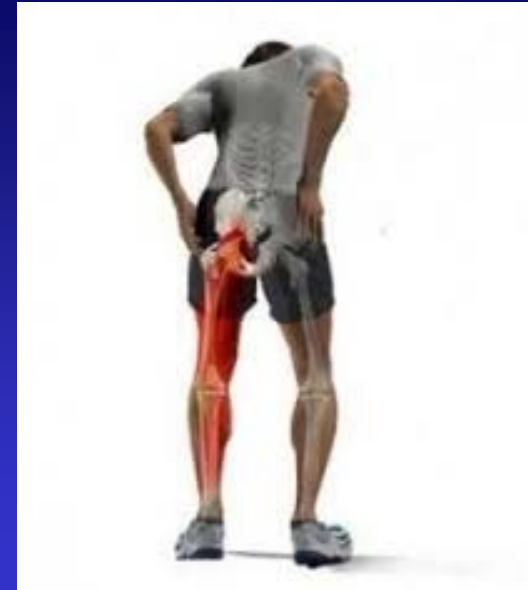ORTHOSPORTS

Specialist Sports Injury & Rehabilitation

Dr Paul Annett
Sport & Exercise Medicine Physician

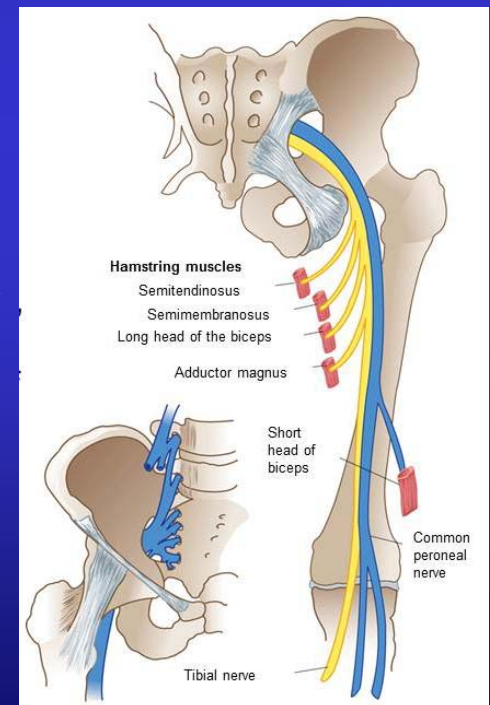
Sciatica

- Why this talk???
- Why is sciatica important?
- Common – Incidence 1-5% annually and 15-40% lifetime
- Debilitating – pain/neurological
- May have consequences



Sciatica

- Distinguishing ‘The Sciatic’ from leg pain
- Sciatic nerve L4-S3 nerve roots
- It has a lumbar, pelvic and gluteal course before entering the posterior thigh



Dr Paul Annett

Sport & Exercise Medicine Physician

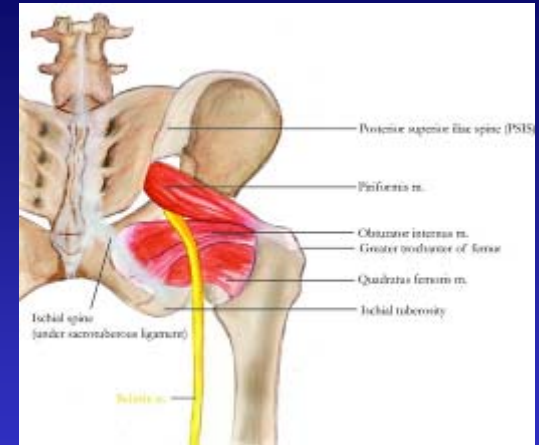


ORTHOSPORTS

100, 200, 300, 400, 500, 600, 700, 800, 900, 1000

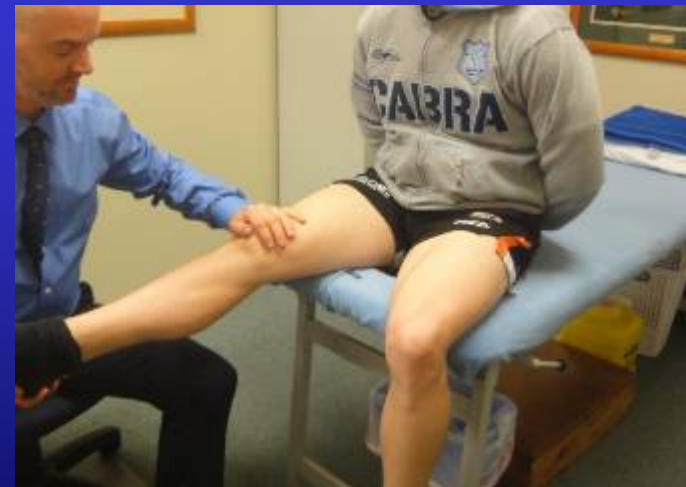Case History #2

- 15 F.
- Radicular sounding L leg pain. Nil precipitant
- CT L5/S1 only. Normal
- 12 months physio – 2 practitioners
- Diagnosed / referred for ‘piriformis syndrome’



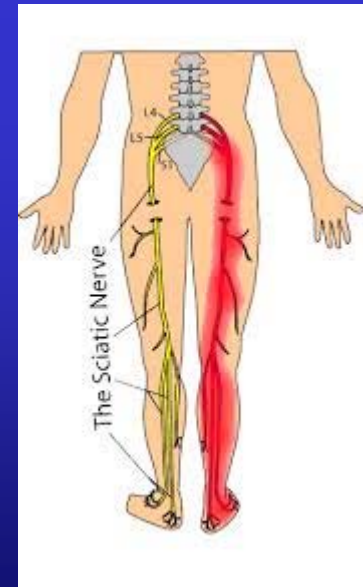
Case History #2

- Clinical Exam
- Lumbar restriction 30 degrees
- Strongly positive NTT with cross-over signs
- SLR 30 degrees
- Normal neurology



Sciatica - Causes

- By definition sciatic nerve irritation
- Anywhere along the course of the nerve
- Lumbar easily the most common
- Consider other sites
 - Pelvis
 - Buttock
 - Posterior thigh
 - Infection (viral)



Dr Paul Annett

Sport & Exercise Medicine Physician

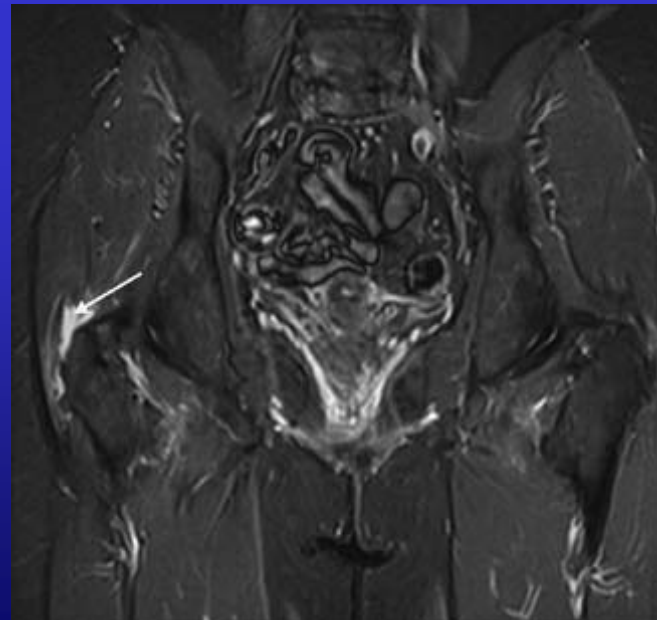


ORTHOSPORTS

100, 101, 102, 103, 104, 105, 106, 107, 108, 109, 110, 111, 112, 113, 114, 115, 116, 117, 118, 119, 120, 121, 122, 123, 124, 125, 126, 127, 128, 129, 130, 131, 132, 133, 134, 135, 136, 137, 138, 139, 140, 141, 142, 143, 144, 145, 146, 147, 148, 149, 150, 151, 152, 153, 154, 155, 156, 157, 158, 159, 160, 161, 162, 163, 164, 165, 166, 167, 168, 169, 170, 171, 172, 173, 174, 175, 176, 177, 178, 179, 180, 181, 182, 183, 184, 185, 186, 187, 188, 189, 190, 191, 192, 193, 194, 195, 196, 197, 198, 199, 200

Sciatica - Mimics

- Gluteal tendinopathy/bursitis
- Hamstring Origin tendinopathy
- Lumbar referred (non-radicular)
- SIJ
- Hip joint
- Soft tissue



Dr Paul Annett

Sport & Exercise Medicine Physician

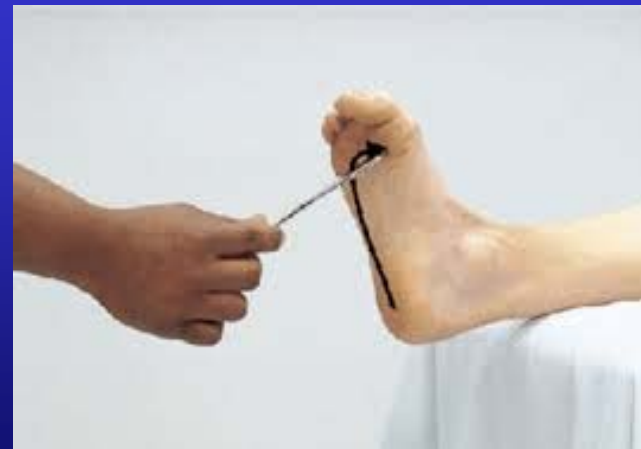True Sciatica - History

- May or may not be a history of back injury
- Leg pain, not always back pain
- Generally unremitting pain
- Buttock, posterior thigh, calf lateral leg, foot. 'Refers past the knee'
- Neuralgic symptoms – weakness, numbness, para/dysaesthesia



True Sciatica - History

- Don't forget cauda equina syndrome
- Bowel or bladder symptoms
- Always consider in unusual presentations
(Eg. Lateral knee pain)



Dr Paul Annett

Sport & Exercise Medicine Physician



ORTHOSPORTS

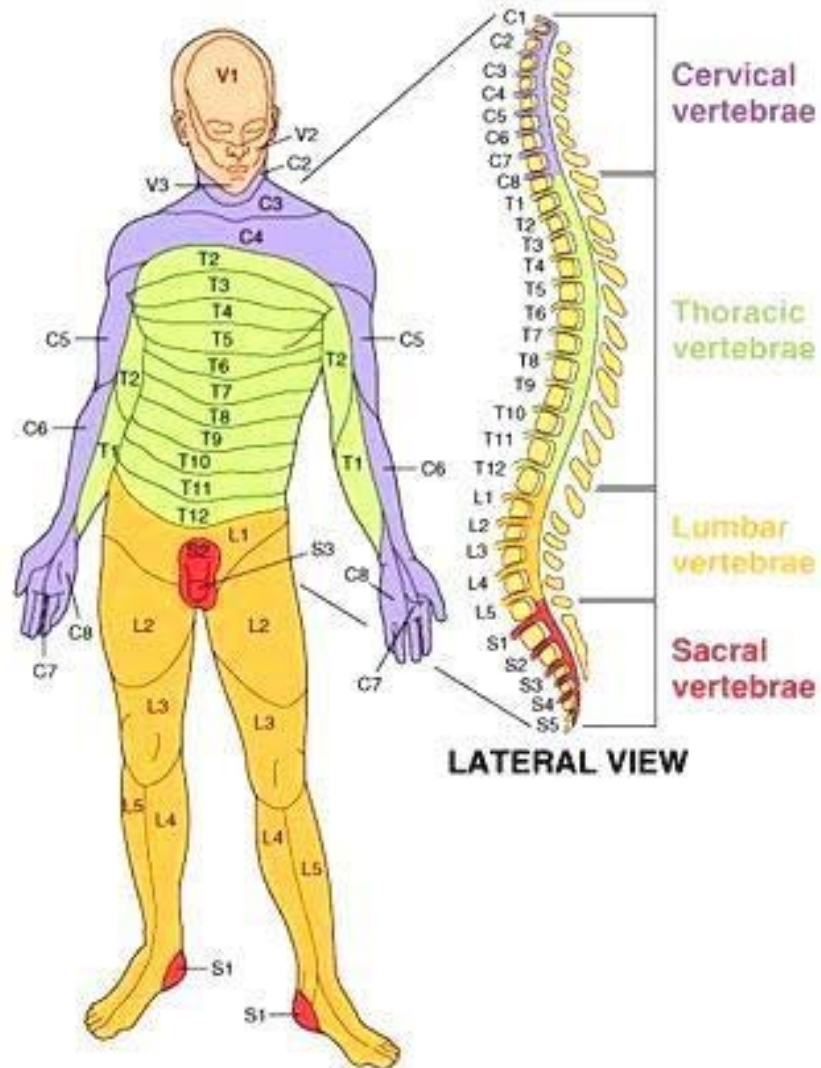

100, 200, 300, 400, 500, 600, 700, 800, 900, 1000

True Sciatica - Examination

- Restricted flexion/quadrant pain
- Hard neurological signs
- Weakness – EHL, calf raise, Trendelenburg
Numbness – dermatomal
- Reflexes – AJ/KJ/plantar
- Neural tension signs. Cross-over!
- Positive SLR less than 30 degrees

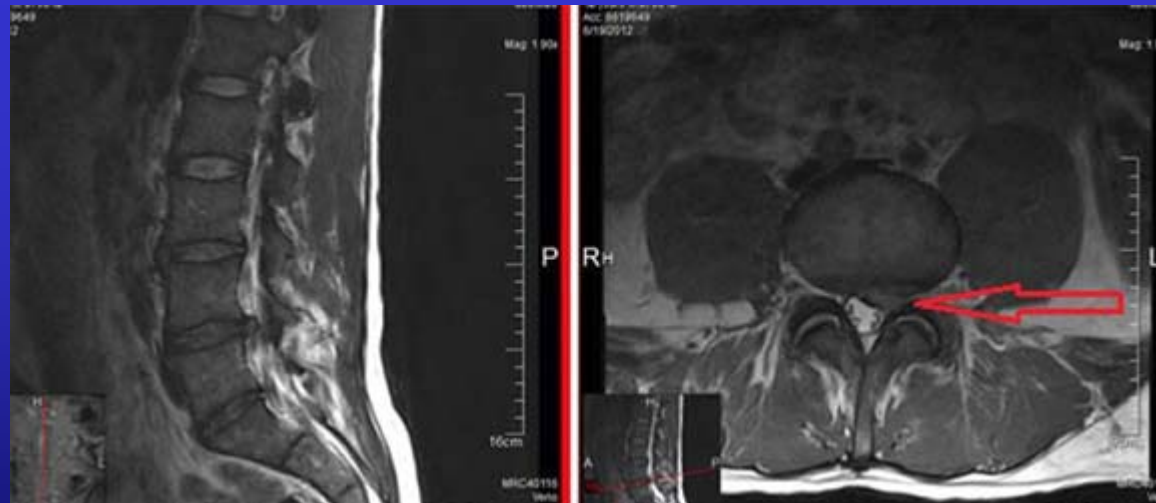


Sciatica - Examination



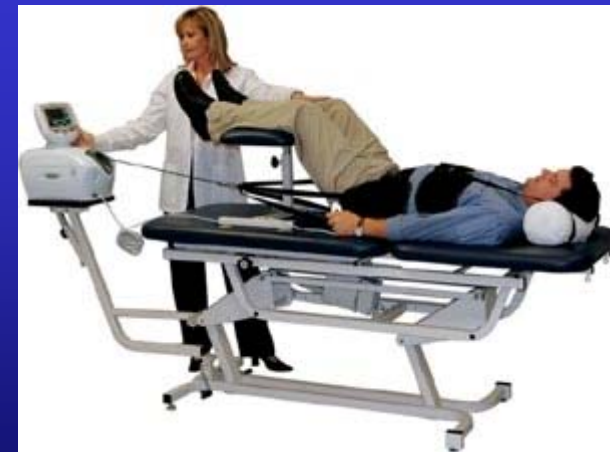Sciatica -Investigation

- MRI gold standard
- CT a reasonable alternative
- Plain Xray
- Timing



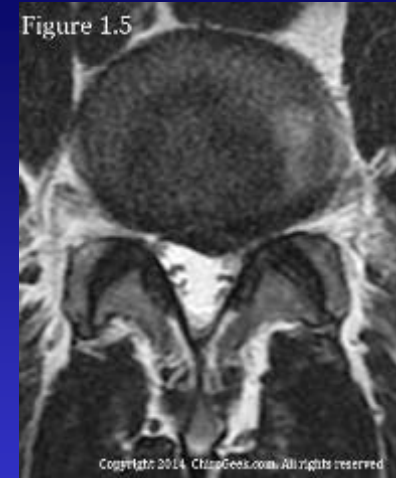
Sciatica - Treatment

- Expectant – favourable outcomes
- Medications
- Physiotherapy + Rehabilitation
- Nerve root blocks
- Surgery - Indications



Case #2 Outcome

- True sciatica
- MRI – ‘moderately large R/central disc prolapse compressing L5 nerve root’
- Nerve root block unhelpful
- Surgery – ‘R L5 discectomy’
- Good surgical outcome with resolution of right leg pain



ORTHOSPORTS

Specialist in Sports Injury & Rehabilitation

Dr Paul Annett
Sport & Exercise Medicine Physician

Sciatica - Take home Message

- Consider in all causes of leg pain
- ‘True’ sciatica vs ‘leg pain’
- Always look for hard signs
- Improvement is generally expected
- Consider surgery with severe pain, worsening neurologic function, prolonged symptoms




ORTHOSPORTS

011 955 1234 5678 9012 3456 7890 1234 5678 9012 3456 7890

Dr Paul Annett
Sport & Exercise Medicine Physician

Thank You



4011 4th Street NW, Ste. 4100

Dr Paul Annett
Sport & Exercise Medicine Physician