

Dr Kwan Yeoh

www.orthosports.com.au

47-49 Burwood Road, Concord
29-31 Dora Street, Hurstville
119-121 Lethbridge Street, Penrith



ORTHOSPORTS

ORTHOPAEDIC & SPORTS MEDICINE SERVICES

Dr Kwan Yeoh

Hand, Upper Limb & General Orthopaedic Surgery

Triangular fibrocartilage complex (TFCC)

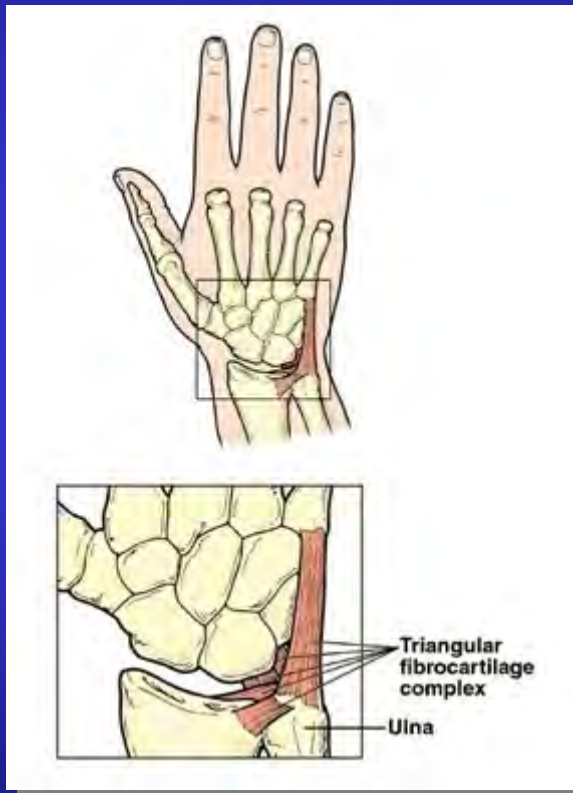


ORTHOSPORTS

ORTHOPAEDIC & SPORTS MEDICINE SERVICES

Dr Kwan Yeoh
Hand, Upper Limb & General Orthopaedic Surgery

What is it?

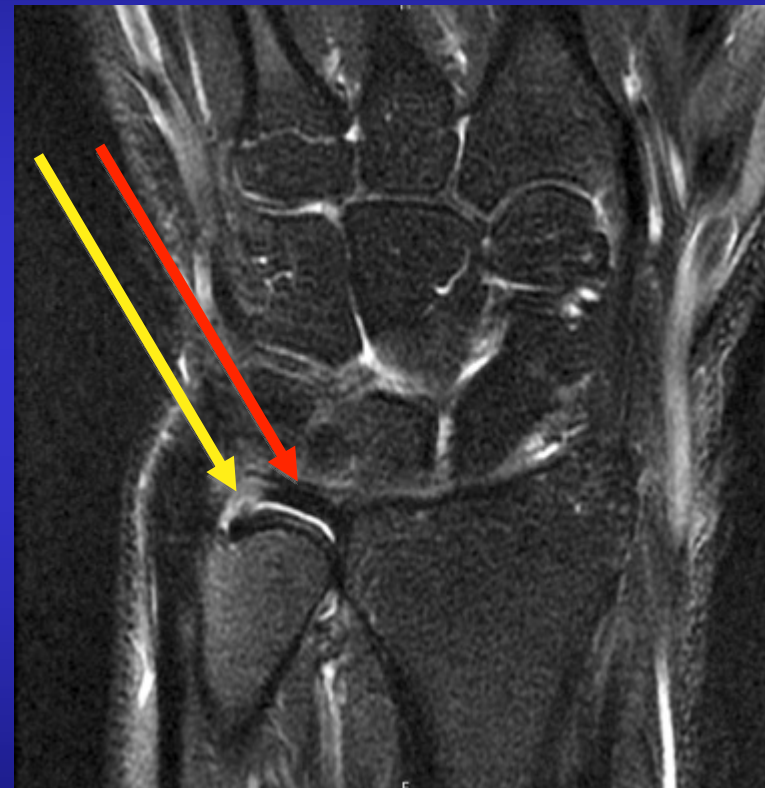
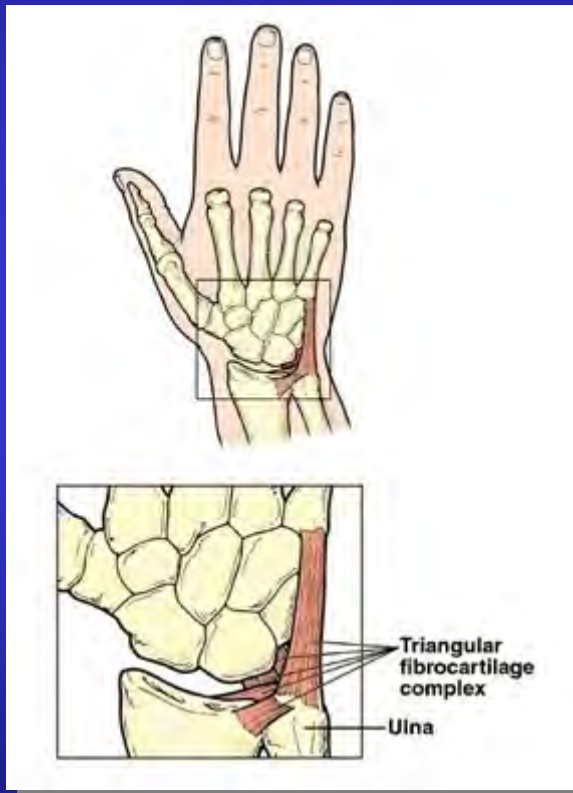


ORTHOSPORTS

ORTHOPAEDIC & SPORTS MEDICINE SERVICES

Dr Kwan Yeoh
Hand, Upper Limb & General Orthopaedic Surgery

Tears



ORTHOSPORTS

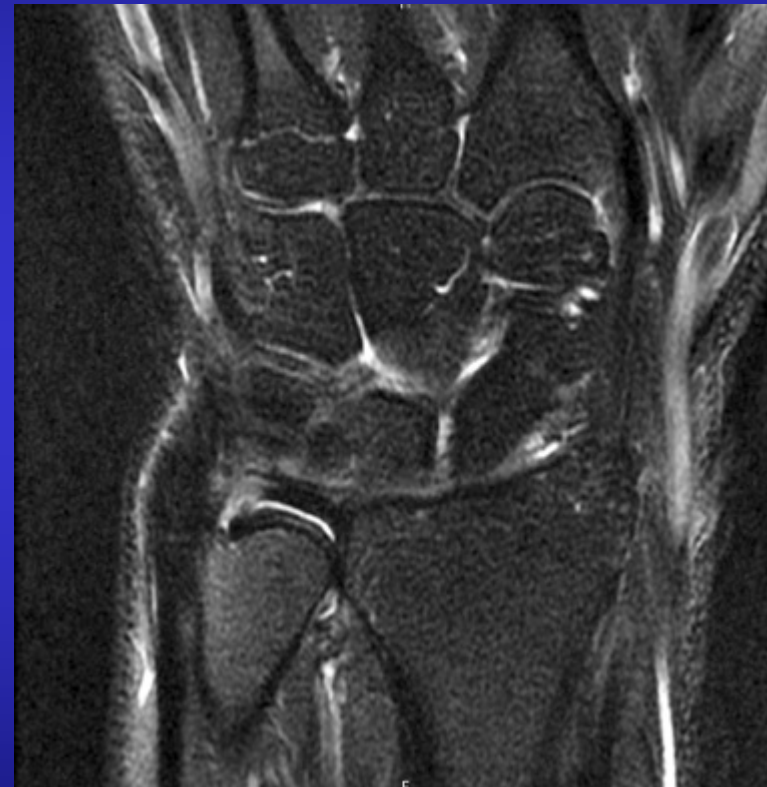ORTHOPAEDIC & SPORTS MEDICINE SERVICES

Dr Kwan Yeoh
Hand, Upper Limb & General Orthopaedic Surgery

Tears

Class 1 = Traumatic

Class 2 = Degenerative



ORTHOSPORTS

ORTHOPAEDIC & SPORTS MEDICINE SERVICES


Dr Kwan Yeoh
Hand, Upper Limb & General Orthopaedic Surgery

Tears

Class 1 = Traumatic



Class 2 = Degenerative



ORTHOSPORTS

ORTHOPAEDIC & SPORTS MEDICINE SERVICES

Dr Kwan Yeoh
Hand, Upper Limb & General Orthopaedic Surgery

Assessment

History

Ulnar-sided pain

Tenderness

Ulnocarpal grind

DRUJ stability



ORTHOSPORTS

ORTHOPAEDIC & SPORTS MEDICINE SERVICES

Dr Kwan Yeoh

Hand, Upper Limb & General Orthopaedic Surgery

Investigations

X-ray

MRI

Injection



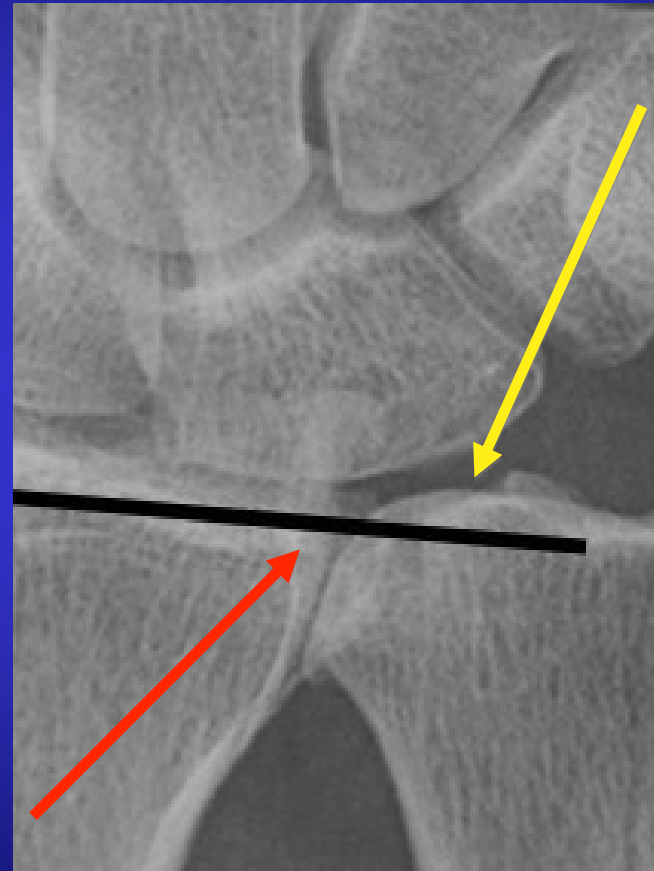
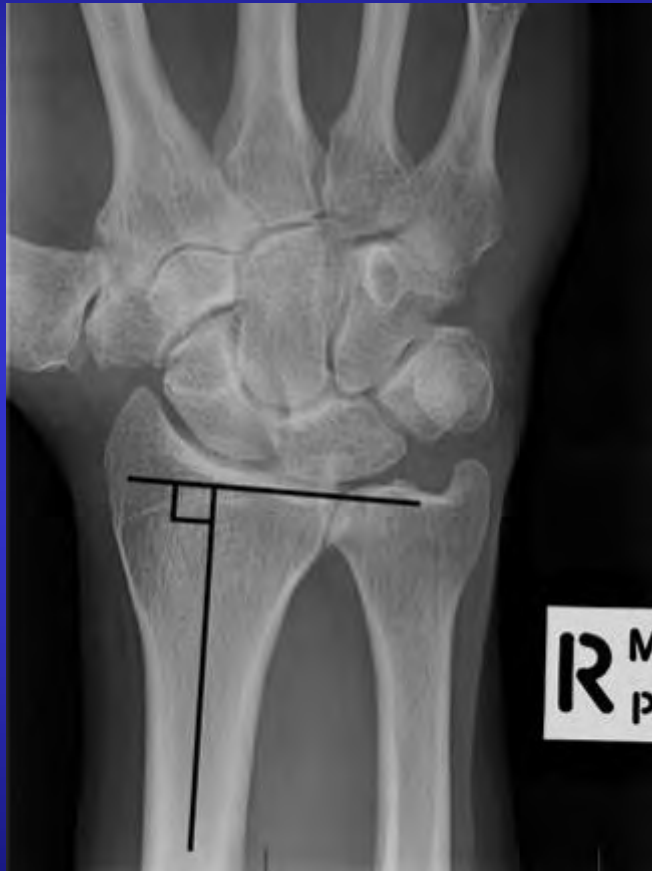ORTHOSPORTS

ORTHOPAEDIC & SPORTS MEDICINE SERVICES

Dr Kwan Yeoh

Hand, Upper Limb & General Orthopaedic Surgery

X-ray



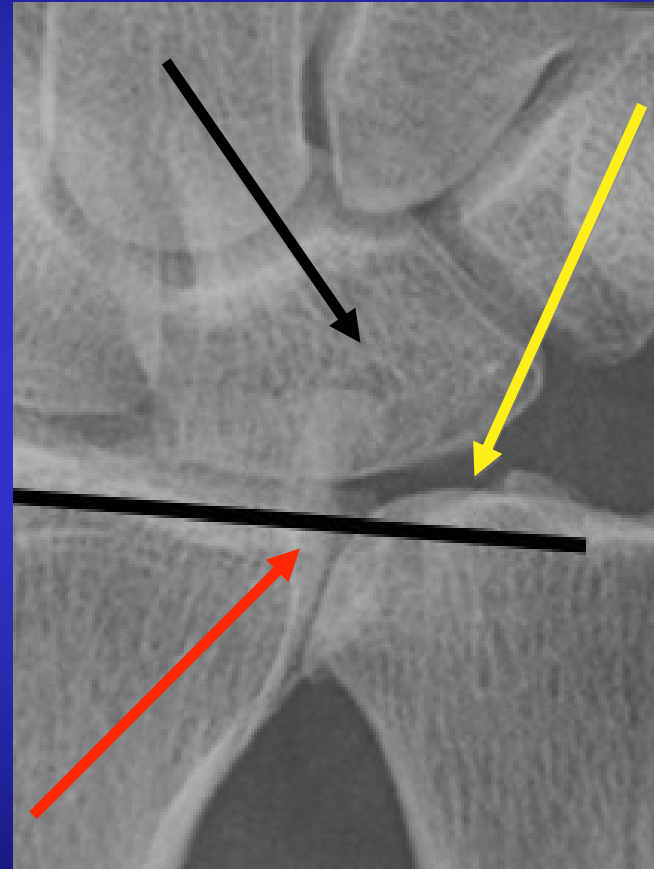
ORTHOSPORTS

ORTHOPAEDIC & SPORTS MEDICINE SERVICES

Dr Kwan Yeoh
Hand, Upper Limb & General Orthopaedic Surgery

X-ray

Ulnar variance

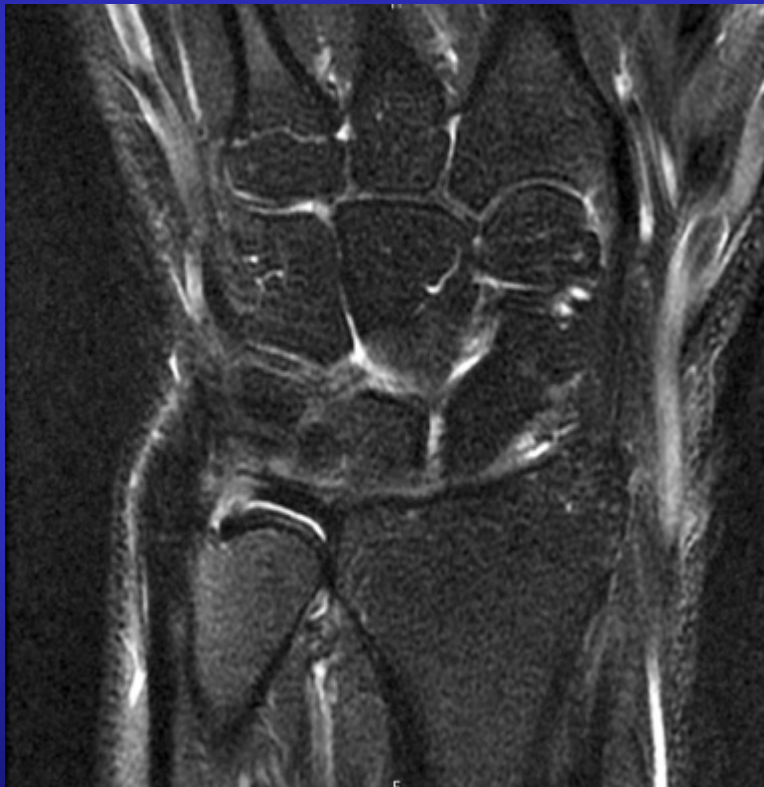

ORTHOSPORTS

ORTHOPAEDIC & SPORTS MEDICINE SERVICES

Dr Kwan Yeoh
Hand, Upper Limb & General Orthopaedic Surgery

MRI



- False negatives
 - Sensitivity 82-90%
- False positives
 - TFCC tears in 37.8% of asymptomatic wrists



ORTHOSPORTS

ORTHOPAEDIC & SPORTS MEDICINE SERVICES

Dr Kwan Yeoh
Hand, Upper Limb & General Orthopaedic Surgery

Investigations

X-ray

MRI

Injection



ORTHOSPORTS

ORTHOPAEDIC & SPORTS MEDICINE SERVICES

Dr Kwan Yeoh

Hand, Upper Limb & General Orthopaedic Surgery

Natural history

- TFCC tear associated with distal radius fractures:
 - Trend to poorer outcomes
 - Operative repair in 2.6%



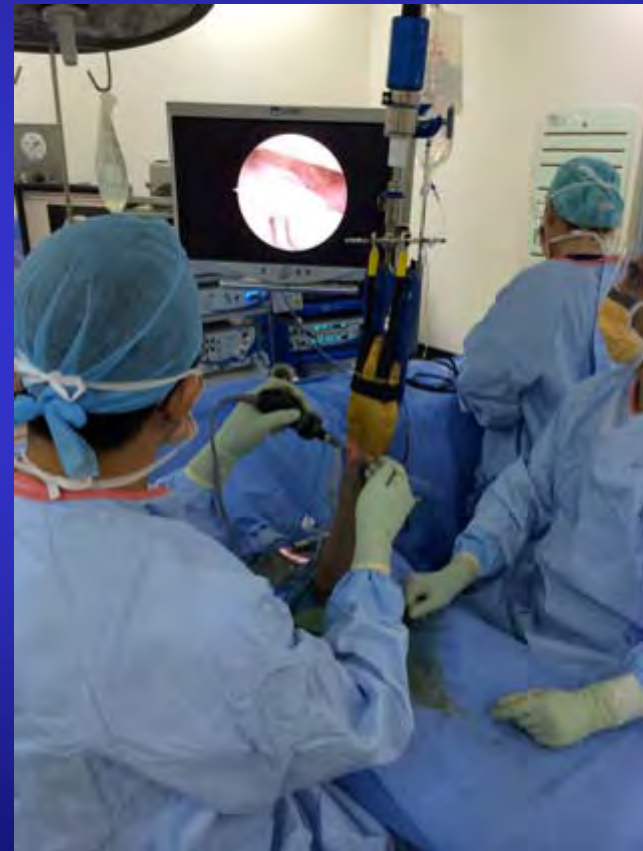ORTHOSPORTS

ORTHOPAEDIC & SPORTS MEDICINE SERVICES

Dr Kwan Yeoh
Hand, Upper Limb & General Orthopaedic Surgery

Management of acute tear

- DRUJ unstable
 - Reducible DRUJ & peripheral tear:
 - Immobilise, position of stability, 6 weeks
 - Operative repair



Dr Kwan Yeoh

Hand, Upper Limb & General Orthopaedic Surgery

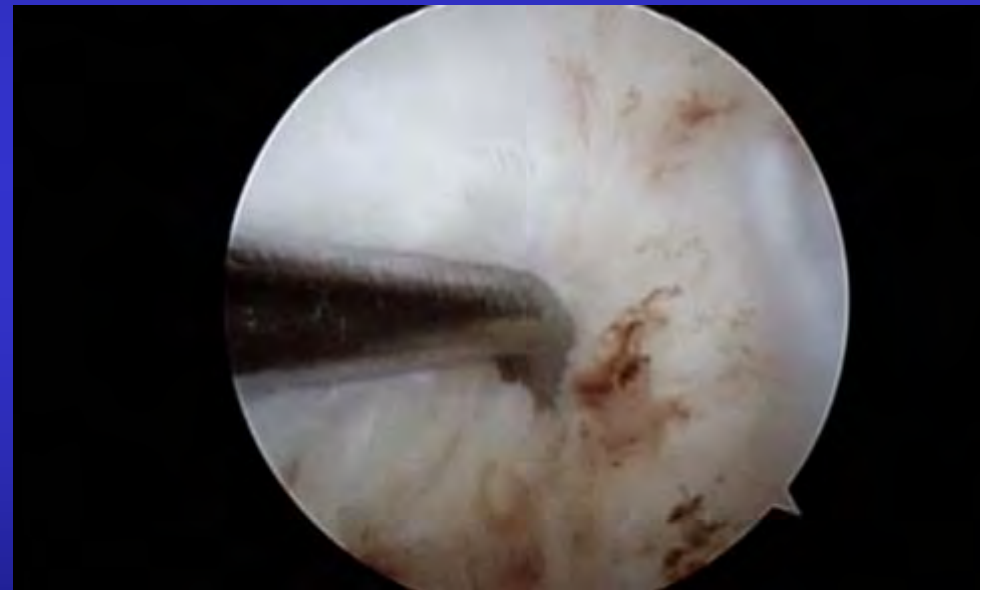

ORTHOSPORTS

ORTHOPAEDIC & SPORTS MEDICINE SERVICES

Management of acute tear

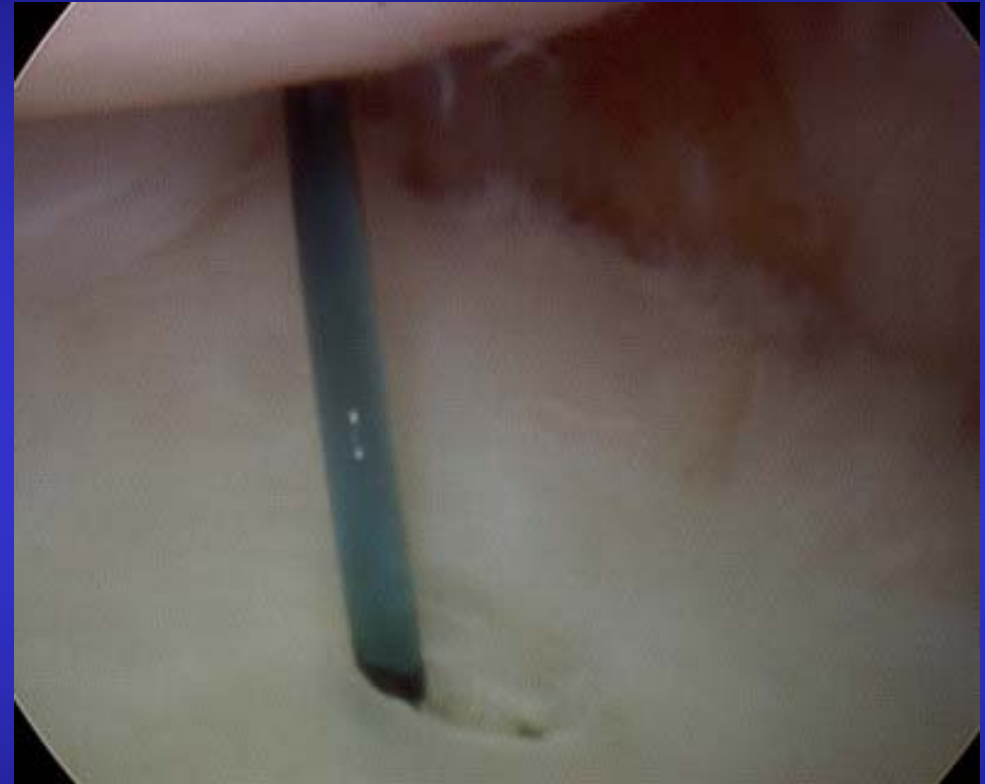
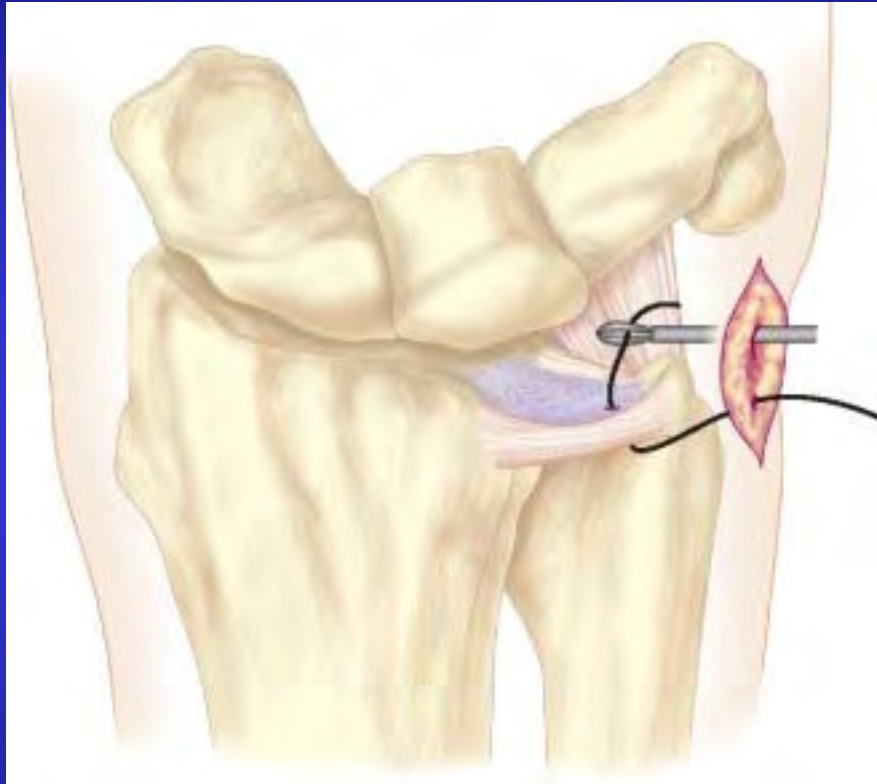- DRUJ stable
 - Splint, NSAIDs, steroid injection, ROM, strength
 - Operative repair if symptomatic at 3 months



ORTHOSPORTS

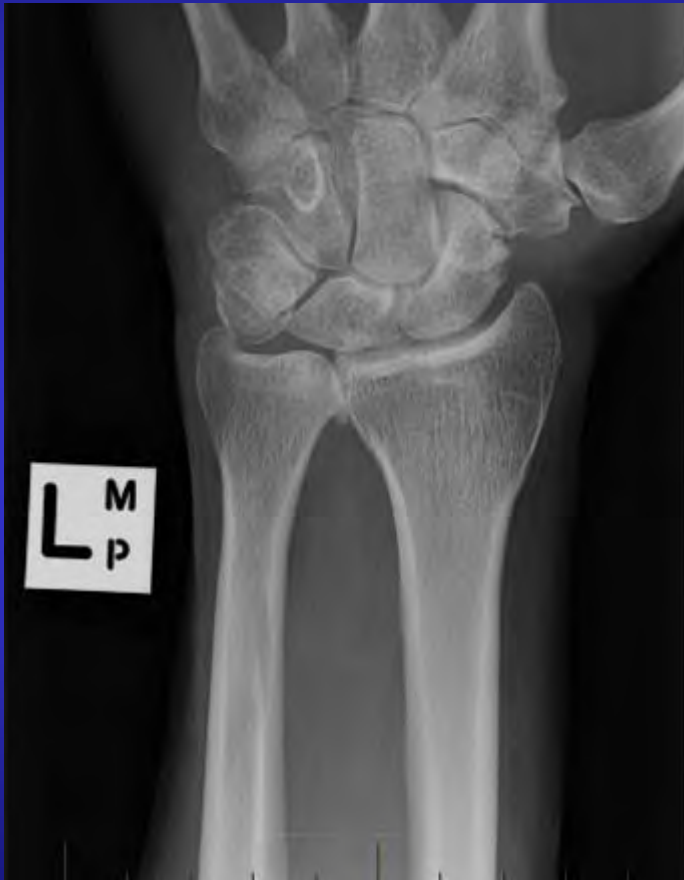ORTHOPAEDIC & SPORTS MEDICINE SERVICES

Dr Kwan Yeoh
Hand, Upper Limb & General Orthopaedic Surgery



Images: Slutsky, Tech wrist hand arthroscopy 2007

Management of chronic tear



- Non-operative + activity modification
- Operation:
 - Debridement
 - Ulnar shortening osteotomy

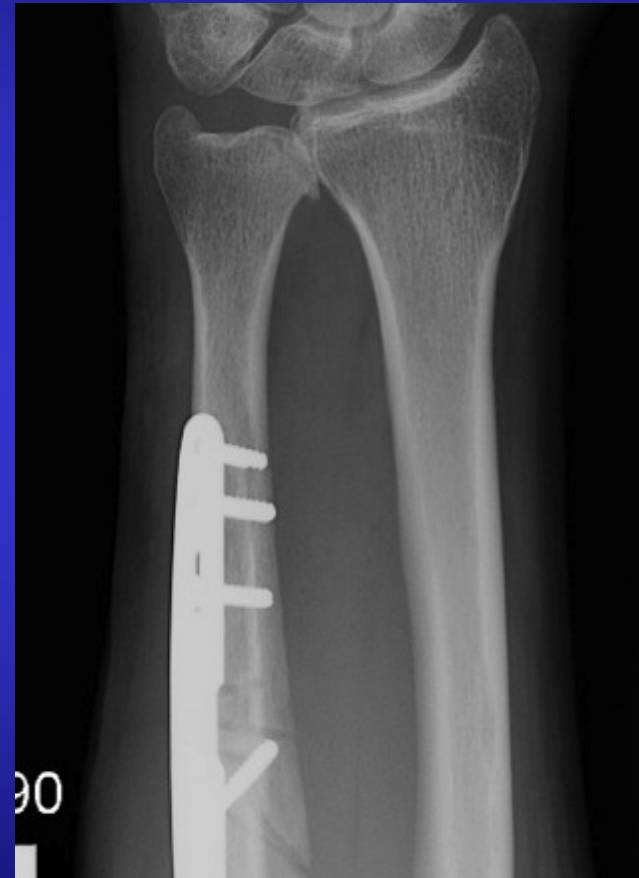
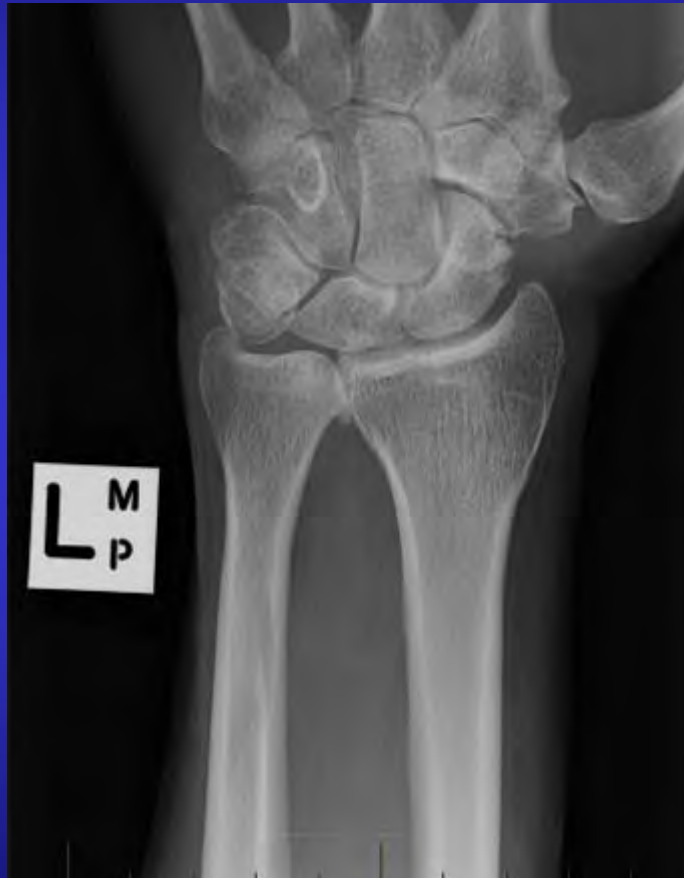

ORTHOSPORTS

ORTHOPAEDIC & SPORTS MEDICINE SERVICES

Dr Kwan Yeoh
Hand, Upper Limb & General Orthopaedic Surgery

Management of chronic tear



ORTHOSPORTS

ORTHOPAEDIC & SPORTS MEDICINE SERVICES

Dr Kwan Yeoh
Hand, Upper Limb & General Orthopaedic Surgery

Take home message

Early management is dictated by
DRUJ stability



ORTHOSPORTS

ORTHOPAEDIC & SPORTS MEDICINE SERVICES

Dr Kwan Yeoh
Hand, Upper Limb & General Orthopaedic Surgery

Dr Kwan Yeoh

www.orthosports.com.au

47-49 Burwood Road, Concord
29-31 Dora Street, Hurstville
119-121 Lethbridge Street, Penrith



ORTHOSPORTS

ORTHOPAEDIC & SPORTS MEDICINE SERVICES

Dr Kwan Yeoh
Hand, Upper Limb & General Orthopaedic Surgery